

Limb Lengthening by Implantable Limb Lengthening Devices

*Dror Paley, MD, FRCSC, Matthew Harris, MD, MBA,
Kevin Debiparshad, MD, FRCSC, and Daniel Prince, MD, MPH*

Summary: Implantable limb lengthening using noninvasively adjusted telescopic nails dates back to 1983. The newest technology is the Precice (Ellipse Technologies). A retrospective study of the first 65 Precice nails was carried out for the treatment of limb length discrepancy (unilateral) and short stature (bilateral). Successful lengthening was achieved in all patients. There were numerous distraction and hardware complications. Despite these, implantable limb lengthening appears to be the direction for the future of limb lengthening.

Key Words: limb lengthening—distraction osteogenesis—lengthening nails—implantable lengthening nail—leg length discrepancy—stature lengthening.

(Tech Orthop 2014;29: 72–85)

Surgical limb lengthening dates back to the turn of the 20th century with the publication of Codivilla.¹ Over the first half of the 20th century, the lengthening devices ranged from the traction Thomas splint device of Codivilla, to various bed mounted and semiportable external fixation devices. The early limb lengtheners^{2–6} employed distraction osteogenesis to fill the distraction gap produced by their fixators. It was not, however, until the 1950s and 1960s that the biology of distraction osteogenesis became understood. This was largely due to Ilizarov and his group in Kurgan, USSR. Despite their ability to predictably achieve desired length, external fixators are plagued by high complication rates secondary to pin-tract infections, associated risk of deep infection, neurovascular injuries, prolonged treatment time until removal, muscular and soft-tissue transfixation that lead to contractures and stiffness, pain and discomfort, refracture after removal of the fixators, as well as, psychosocial burden, requirement to perform daily pin cleaning, and physical awkwardness^{7–13}

Because of all of the above reasons many postulated and conceived of internal implants^{14–19} to achieve limb lengthening. Implantable limb lengthening using distraction osteogenesis also takes its origins in the Soviet Union. Alexander Bliskunov from Sinferopol, Ukraine first published his method in 1983^{13,20} (Fig. 1). This was before most of the western world had heard of Ilizarov. Bliskunov developed a telescopic lengthening nail that used a crankshaft connected to the pelvis to drive his mechanism and lengthen the femur. Rotational motion of the femur produced lengthening of the nail. The

rotation was through the hip joint and not through the osteotomy. His technology was not available outside of the Soviet Union. Even today it is only used by a few in Ukraine.

Over the last 3 decades, other fully implantable lengthening nails have been developed. Baumgart and Betz from Germany developed a motorized nail in 1991 (now called Fitbone). The Fitbone (Wittenstein, Igersheim, Germany) is a fully implantable lengthening nail whose mechanism is driven by an internal motor that requires an external transmitter. An antenna comes out of one end of the nail and is implanted subcutaneously. It is powered and controlled by radiofrequency and the lengthening is performed at night when the patient is in bed to mimic natural growth. Data are limited, as there are only 3 studies in the English literature that have reviewed a total of 37 implants,^{21–23} although they report good overall results. The series by Singh and colleagues reported that 3/24 nails in 2 patients required later bone grafting. They also had 2 implants that needed to be removed and exchanged for large diameter implants because the gears in the original nails were not strong enough to achieve distraction. Baumgart and colleagues reported that 2/12 nails had faulty motors that required reoperation and only 1 patient required a later bone graft procedure. The Fitbone is the only motorized nail available. It is on limited release. To obtain permission to use it one has to either receive agreement from Dr Baumgart or the Wittenstein company.

Guichet and Grammont from France, developed a telescopic nail in 1994 using a ratchet mechanism which rotated the 2 segments of the nail through the osteotomy and callus of the distraction gap. The Gradual Lengthening Nail also known as Albizzia (Depuy, Villerbuane, France) was later modified and released as the Betzbone and the Guichet nail for use by its 2 namesakes, respectively. It takes 20 degrees of rotation to move the ratchet one notch. Each notch is 1/15 of a millimeter. Many reports exist of patients suffering from severe pain and discomfort, which limit their ability to independently perform the lengthenings. In some cases, these patients required readmission to the hospital with general anesthesia and closed manipulation.^{24–26} In other reports, 12% of the lengthenings remained incomplete because the patients were simply unable to tolerate the pain of the manipulation.²⁵

Using the same concept of lengthening by rotation through the callus, Cole developed a double-clutch mechanism to cause distraction. Only 3 to 9 degrees of rotation was required to cause the nail to lengthen. The intramedullary Skeletal Kinetic Distractor (ISKD) (Orthofix Inc., McKinney, TX) was Food and Drug Administration (FDA) approved in 2001. It was recently removed from the market and is no longer available. As the lengthening was so easy to activate, and as there was no “governor” to the lengthening mechanism, the nail is free to lengthen at any rate. Too rapid distraction was a frequent complication. This was referred to as a “runaway nail” or “runaway lengthening.” Due to the uncontrolled lengthening rate and rhythm the ISKD had a very high

From the Paley Advanced Limb Lengthening Institute, St. Mary's Hospital, West Palm Beach, FL.

Dr. Paley is a paid consultant for Ellipse Technologies. The other authors declare that they have nothing to disclose.

Address correspondence and reprint requests to Dror Paley, MD, FRCSC, Paley Advanced Limb Lengthening Institute, St. Mary's Hospital, 901 45th St., Kimmel Building, West Palm Beach, FL, 33407.
E-mail: drorpaley@gmail.com.

Copyright © 2014 by Lippincott Williams & Wilkins



FIGURE 1. Alexander Bliskunov, 1992: the father of implantable limb lengthening.

complication rate. The nail would often lengthen at a rate that exceeded the ability for distraction osteogenesis of bone and histogenesis of soft tissues leading to many complications. Restriction of activities and bracing were required to try and prevent and control too rapid lengthening. Failure of bone formation required separate bone grafting procedure for deficient regenerate.²⁷⁻³⁰

Arnaud Soubieran from France developed the Phenix nail. The Phenix has a mechanism activated by a large external, hand-held magnet. By rotating the magnet around the leg an internal crankshaft mechanism in the nail was rotated. This led to traction on a wire pulley, which caused distraction of the nail. The mechanism for the Phenix was first used in a spinal distractor, and, in a lengthening prosthesis manufactured by the same company. Rotating the magnet one direction leads to lengthening, whereas rotating it the other way leads to shortening. This device was self marketed by Soubieran until 2012 at the time of his accidental death. The Phenix produced excellent results in the small number of cases in which it was used. There were anecdotal reports that the nail was not able to

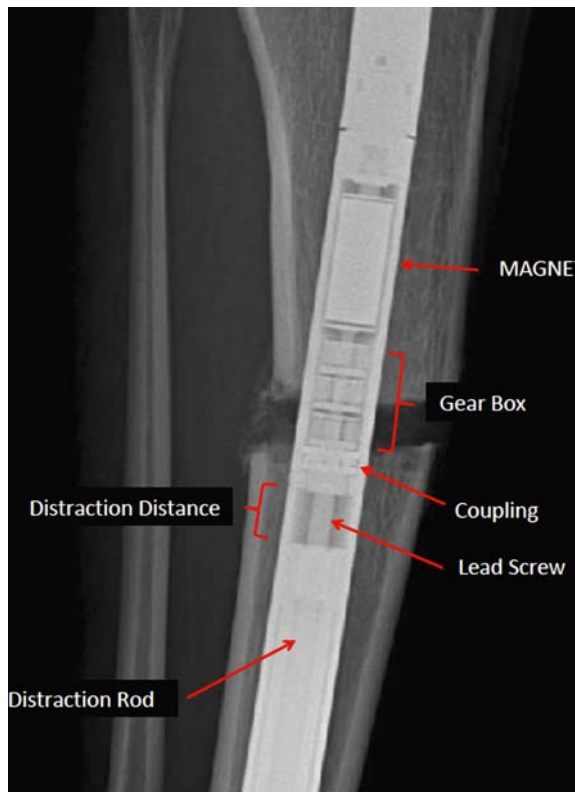


FIGURE 2. Radiograph of the nail showing the different parts of the mechanism. full color online

lengthen against too much force. A version of his mechanism is contracted to Smith and Nephew and awaits FDA clearance and release.

Ellipse Technologies (Ellipse Technologies, Irvine, CA) developed the Precice nail with a team of surgeons headed by Dr Stuart Green. Ellipse used the same mechanism that they had developed for their spinal growing rod called “the MAGEC System.”³¹ There is a magnetic metal spindle that is connected to a series of gears (Fig. 2). The gears are connected to a coupling, which is connected to a threaded drive shaft. The mechanism is activated by an external remote control (ERC) device (Fig. 3). The ERC employs 2 motor-driven rotating

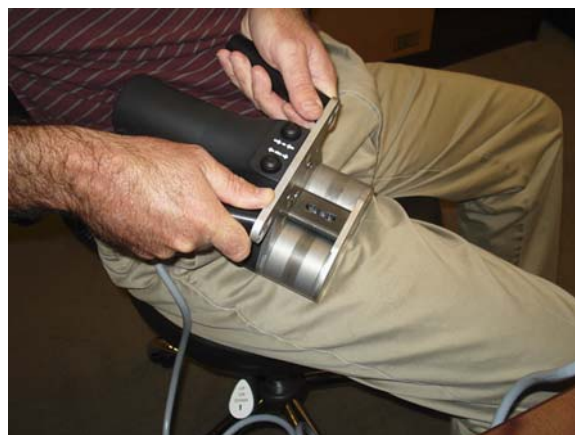

FIGURE 3. The external remote control (ERC) device.

magnets to magnetically couple to and rotate the magnetic metal pins. The ERC performs 30 revolutions per minute. It takes 7 minutes and 210 revolutions to achieve 1 mm of lengthening. Facing the ERC 1 direction causes the nail to lengthen, whereas facing it the other direction would go in the reverse (shortening) direction. The Precice is the second FDA-cleared implantable lengthening nail device (July 2011) and the first one to have bidirectional control (lengthening and shortening). I had the privilege of implanting the first Precice nail in the United States on December 1, 2011. The initial experience with this device in the United States and several countries around the world has been excellent. Nevertheless, there have been many lessons from the learning curve of this device. The purpose of the rest of this paper is to review the surgical technique and lessons from the first 65 nails implanted in a consecutive series of 48 patients at a single center.

PRECICE NAIL

The Precice 1 nail used in this study is made up of 2 parts that are connected together by the surgeon; the modular locking segment and the rest of the nail, which contains the mechanism and the telescopic parts. The mechanism housing is welded to the rest of the larger diameter tube of the nail. There are a total of 3 welds in the larger diameter tube of the nail and 1 set screw connection point to add various type and length insertion segments. The fully constructed nail is available in lengths of 230, 255, 280, 305, 330, and 355 mm. To change the length, different locking segments are used. The maximum distraction (stroke) for each of these nails is 6.5 cm.

Preoperative planning is important before surgery to determine the ideal nail length, insertion point (eg, trochanteric vs. piriformis), osteotomy level, and direction of the nail (antegrade vs. retrograde). The nail length and osteotomy level are very interrelated. To avoid too much friction the osteotomy level is planned to leave 1 to 3 cm of the wider tube of the nail engaged in the opposite segment of the bone (this is explained in detail below). When there is a larger femoral bow we prefer to make the osteotomy at the level of the apex of the bow. Working backwards this can help calculate the ideal length of the nail to use. In most cases a relatively short nail is used compared with nailing for fixation of fractures. The femur can be reamed with flexible or straight rigid reamers. The latter are less available and less forgiving. However, they conform to the shape of the nail better and are preferred if available. Piriformis start is preferred in most adult femurs unless there is a coxa breva or valga. In children with open proximal femoral physes, a trochanteric start point is preferred to minimize the risk of avascular necrosis. Retrograde nailing is used in the femur in conjunction with angular deformity correction of the distal femur or if there is a quadriceps lag that needs to be tightened (1 case in the series below had retrograde nailing for the quadriceps lag). Retrograde tibial nailing is used in patients with pantalar arthrodesis.

AUTHOR'S SURGICAL TECHNIQUE FEMUR

Step 1: The patient is positioned supine on a radiolucent operating table (Fig. 4). A radiolucent bump (usually a folded towel or sheet) is placed underneath the ischium on the operative side. This allows good visualization of the hip on both anteroposterior (AP) and cross table lateral views (Fig. 4).

Step 2: Using the image intensifier (fluoroscopy) the tip of the level of the greater trochanter is marked on the skin.

Knowing the length of the nail to be used for the surgery, a ruler is used to mark the distal end of the nail.

Step 3: The level of the osteotomy is determined by knowing the amount of distraction planned. One must plan to end up with the larger diameter of the nail always engaged on both sides of the distraction gap at the end of lengthening. Assuming one wants to have 2 cm of the larger diameter of the nail engaged, then add 2 cm plus the 3 cm of smaller diameter nail, which is exposed plus the distraction amount. This total measured from the distal end of the nail represents the level of the desired osteotomy that will leave at least 2 cm of the larger diameter of nail always engaged.

Step 4: Make a 1-cm incision laterally at the level of the osteotomy. Drill holes using a 4.8-mm drill bit. I prefer one entrance and 3 exit holes; anteromedial, anterolateral, and medial. Then make 2 more holes anterolateral and posterolateral at the level of the other holes. These holes will serve to vent the canal from fat emboli and to allow the reamings that spill out to help fertilize the bone formation at the distraction gap.

Step 5: Get your starting point using a Steinmann pin in the piriformis fossa for adults or children with closed growth plates. Enlarge this opening using an anterior cruciate ligament (ACL) reamer. For open growth plates, insert the Steinmann pin into the tip of the greater trochanter.

Step 6: Open the fossa or trochanter with an ACL reamer.

Step 7: Insert a beaded guide rod down the femur.

Step 8: Ream in 1-mm increments until there is chatter and then in ½-mm increments. Ream to 12.5 mm for the 10.7 mm nail and to 14.5 mm for the 12.5 mm nail.

Step 9: Prepare the nail for insertion. With Precice 1, choose and assemble the insertion end type (trochanteric, piriformis, retrograde, tibial) and lengths. The mechanism comes in 1 length, whereas the final nail length depends on the length of the insertion end chosen. With the new Precice 2, the nail is not modular and one must choose the length of the entire nail in advance.

Step 10: Apply the proximal targeting device and test its alignment to the screw holes by inserting the drill guides and bits.

Step 11: Place the nail under the beam of the image intensifier to see if the mechanism is not predistracted. Save this image for reference.

Step 12: Remove the initial beaded guide wire used for reaming, as the nail is not cannulated. Insert the nail into the canal up to the level of the planned osteotomy (drill holes).

Step 13: Have one assistant lift the foot off the table. Have the other assistant lift the proximal end of the nail using the insertion guide. The two assistants are applying an extension moment to the femur to prevent displacement of the femur during the osteotomy.

Step 14: Use a sharp osteotome to osteotomize the femur through the 1-cm lateral incision. The femur will easily break through the 6 drill holes. Listen for the break and once it occurs withdraw the osteotome. Test that the femur is fractured while maintaining the extension moment. Move the femur gently into varus and valgus and watch it move on the image intensifier.

Step 15: Once the break is confirmed to be complete, advance the nail by gently hammering on the impactor until the upper end is at the level of the base of the piriformis fossa or just inside the greater trochanter for piriformis and trochanteric nails, respectively.

Step 16: Lock the nail proximally with 2 screws. For distal locking screws, my personal preference is to insert a long 1.8-mm wire into the locking hole, followed by a 3.8-mm cannulated drill for the distal 10.7 nails and a 4.8-mm cannulated drill for the

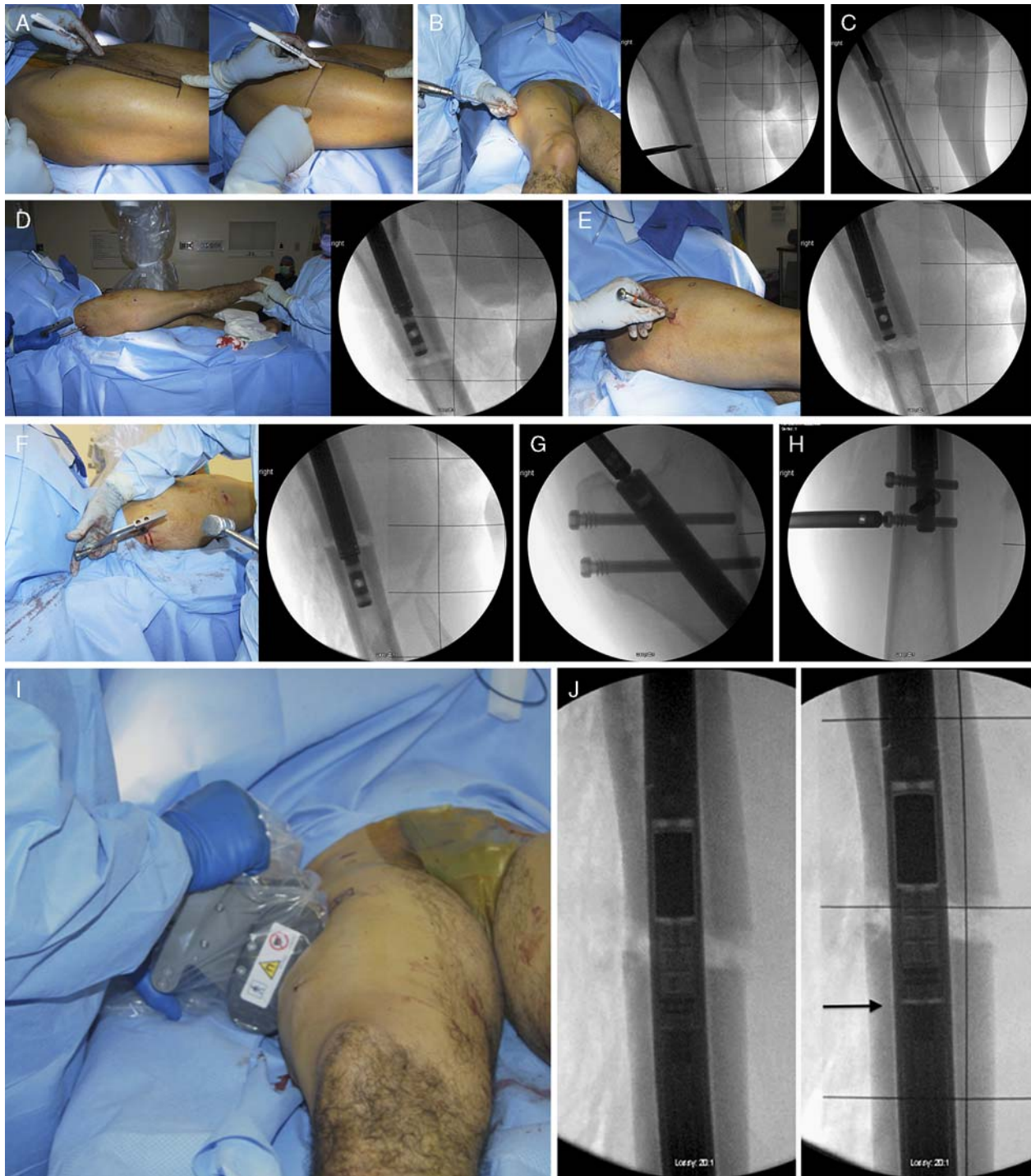


FIGURE 4. Surgical Technique step by step. A, Mark the level of the greater trochanter and the lower end of the nail (left). Then measure back from the tip of the nail as outlined in the manuscript (right). This is the osteotomy level. B, Through a 1-cm incision, drill holes at the level of the planned osteotomy. C, Ream the femur in increments. The reamings exit the drill holes. D, Insert the nail to the level of the osteotomy and then apply an extension moment to the femur by holding it up at the heel and lifting on the insertion guide. E, Use an osteotome percutaneously to complete the osteotomy. F, Maintain the extension moment until the nail crosses the osteotomy into the distal segment. G, Lock the nail proximally with 2 screws. Insert the end cap. H, Lock the nail distally with 2 frontal plane screws (I now prefer to leave out the AP third screw). I, Now apply the external remote control device for 7 minutes to do 1 mm of distraction. J, X-ray before distraction (left) and after distraction (right). Note the clear space after distraction of 1 mm (arrow).

distal 12.5-mm drills. In the 10.7 mm over drill with a solid 4.0 mm drill after removing the cannulated one.

Step 17: Lock the nail distally with 2 screws. Avoid inserting the anteroposterior middle screw because it can act as a stress riser for fracture of the femur.

Step 18: Insert the end cap into the proximal part of the nail.

Step 20: Close all the incisions.

Step 21: Insert the ERC device into a sterile sleeve. Mark out the level of the magnet on the skin using fluoroscopy. Apply, the ERC directly over the magnetic spindle, using the image intensifier to mark out the magnet. It takes 7 minutes to lengthen the femur 1 mm. Remember to program the ERC for antegrade or retrograde use.

Step 22: Check if the distraction gap is seen radiographically and compare it to the predistraction space. If an objective increase in space is seen the procedure is completed. If not do a second millimeter of distraction to confirm. In the rare case where the bone does not separate, the nail must be extracted and tested on the bench and if it does not distract then replaced with another nail. An incomplete osteotomy can cause a failure of distraction and can even lead to failure of the mechanism due to the high force of resistance.

SURGICAL TECHNIQUE TIBIA

Step 1: Mark the proximal and distal end of the nail as before.

Step 2: Mark the level of the osteotomy as before.

Step 3: Make a single drill hole anteriorly at the level of the tibial osteotomy. Avoid getting into the anterior compartment. Additional holes can be made medially and posteromedially under the subcutaneous border.

Step 4: Insert temporary arthrodesis screws just proximal to the distal tibiofibular joint. Start with a wire from the fibular side and make sure it passes relatively posteriorly into the tibia. This wire should be oriented distal on the fibula and proximal on the tibia. A second wire of equal length can be used to measure the appropriate length of the screw. Bring the wire out the tibial side and then antegrade drill it with a 3.2-mm cannulated drill bit. Measure and insert a solid (necannulated) 4.5-mm screw of the correct length antegrade.

Step 5: Make a 3-cm incision posterolateral in the mid-level of the leg. Dissect between the peroneals and gastrosoleus muscles anterior to the intermuscular septum. Dissect down to the fibula. Incise and elevate the periosteum off of the lateral aspect of the fibula and insert a Hohmann elevator anterior and posterior to the fibula. Make multiple drill holes in the fibula with a 1.8-mm wire. Use a narrow osteotome to break the fibula. Confirm that the osteotomy is complete by displacing the osteotomy.

Step 6: Insert a Steinmann pin into the proximal tibia at the level of the joint in line with the medial tibial spine, medial to the patellar tendon. Start as high and posterior as possible. Use an ACL reamer to open the starting point.

Step 7: Ream the tibia in 1-mm increments until there is chatter and then in ½-mm increments until 12.5 mm for the 10.7-mm nail and 14.5 mm for the 12.5 mm nail.

Step 8: Osteotomize the tibia with a sharp osteotome.

Step 9: Insert the Precice tibial nail down the tibia.

Step 10: Orient the upper end of the nail so that the upper medial locking screw is oriented towards the tibiofibular joint. Drill this screw into the head of the fibula. Insert this screw to fix the tibia and fibula. Lock the second proximal locking screw from the lateral side. If the first drill hole and screw misses the fibula, then lock the fibula separately with another

4.5-mm screw in a retrograde manner using a wire and cannulated drill first.

Step 11: Free hand lock 2 of the 3 distal screws leaving either the middle or distal one empty.

Step 12: Perform a distraction test of 1 mm using the ERC.

PATIENTS AND METHODOLOGY

Data were obtained retrospectively from a consecutive series of 48 patients who underwent placement of 65 Precice implants between December 1, 2011 and December 4, 2012 (Figs. 5–8) (Tables 1 and 2). All patients have completed the distraction and consolidation phases resulting in one of 2 endpoints, either successful healing or nonunion that required a bone grafting procedure. Institutional Review Board approval was obtained for this study.

To be considered eligible for treatment, patients needed to possess a limb leg discrepancy of at least 1.5 cm, or desire to undergo a cosmetic lengthening. Patients were offered internal lengthening with the Precice as long as the diameter of the canal and length of the bone in question was large enough to safely accommodate the implant, there was no evidence of active infection, and there were no associated deformities that precluded its use. They also needed to be capable of undergoing daily physical therapy and lengthening throughout the duration of the distraction at our institution. Initially, all patients were required by the FDA to undergo distraction by a physician. However, as of October 2012, the FDA cleared home use of the mobile ERC unit, allowing patients to perform their distraction at home.

Forty-one patients had 54 nails inserted into the femur. Of these, 36 femoral nails were inserted in skeletally mature patients using a piriformis entry. Twelve nails were inserted via trochanteric entry in skeletally immature patients or femurs with deformities that precluded a piriformis entry (eg, coxa valga). Six femoral nails were inserted in a retrograde manner.

Seven patients underwent tibial lengthenings, accounting for 8 nails. Six were inserted in standard antegrade manner, and 2 were placed retrograde in patients with undergoing simultaneous hind-foot fusions. One patient underwent unilateral humeral lengthening with a nail inserted in a standard antegrade manner. Another patient with tibial hemimelia and a hypertrophic fibula underwent lengthening of his fibula that required 2 implants inserted retrograde in a staged manner to achieve the desired length. The majority of patients were treated with 12.5 mm diameter nails (40) that were 230 mm in length (44).

The mean age of the patients in this series is 25.6 years (10.3 to 58.4 y) with a median of 20.0 years. Twenty-three patients whose mean age was 18.5 years (10.3 to 43.7 y) were treated for congenital limb leg discrepancy. Their mean preoperative goal was 4.91 cm (1.5 to 6.5 cm), whereas the preoperative mean limb length discrepancy (LLD) was 6.27 cm (1.5 to 8.2 cm). Four patients with a mean age of 17.8 years (13 to 27 y) were treated for developmental limb leg discrepancies and had a preoperative mean goal of 3.68 cm (1.5 to 6.5 cm). Six patients were treated for posttraumatic limb length discrepancies. Their mean preoperative goal was 3.48 cm (1.7 to 5.0 cm) and their mean age was 49.0 years (30 to 58 y). In addition to this, 15 patients underwent cosmetic lengthening. Their mean age was 29.7 years (15 to 48 y), baseline height was 166.2 cm (150 to 177 cm), and the preoperative goal of lengthening was 5.64 cm (3.0 to 6.5 cm).

All surgical procedures were performed using the same preoperative planning and intraoperative surgical techniques described above. The osteotomy level was selected based on a

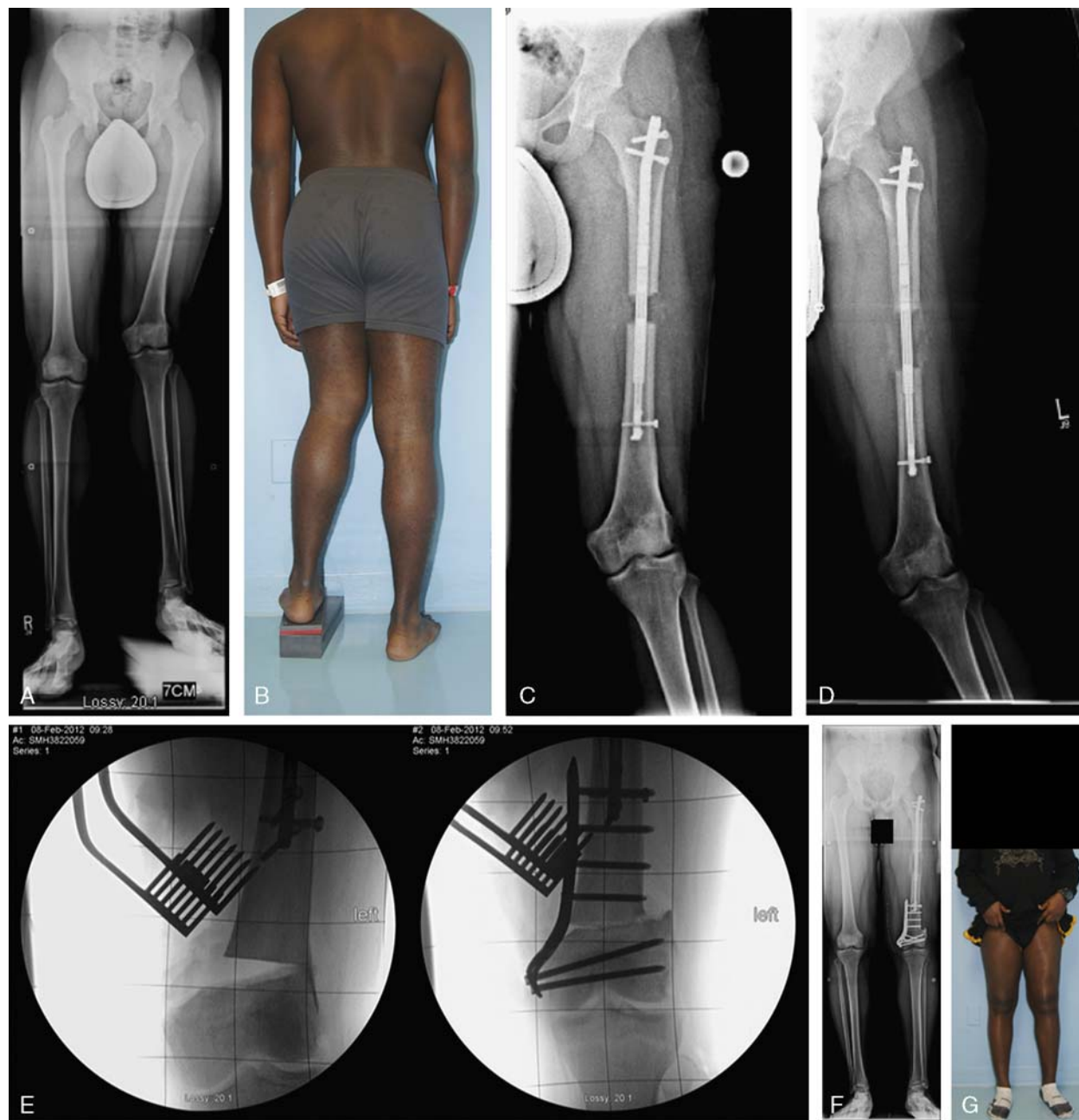

FIGURE 5. A, A 16-year-old boy with 6.5 cm leg length discrepancy and valgus secondary to posttraumatic growth arrest. B, Clinical photo from behind showing the valgus deformity. C, Lengthening with the Precice nail. D, End of lengthening; 6.5 cm. E, Valgus corrected by closing wedge osteotomy with lateral translation. F, The distraction gap is healing well. Alignment is excellent. G, Final clinical photograph after correction.

calculation using the physical specifications of the implant while taking into account the desired overall lengthening. A level was determined that would ensure adequate bony support for both the proximal and distal nail segments throughout the lengthening process. Multiple drill holes were then placed at the planned osteotomy level to allow for venting and dispersion of reamings at the osteotomy site to assist in bone healing. This was followed by reaming of the canal to 2 mm larger than the chosen diameter of the implant. The nail was always distracted between 1.0 and 2.0 mm

intraoperatively, until functionality of the nail and completion of the osteotomy could be confirmed on fluoroscopic imaging.

Patients were discharged from the hospital according to our established protocol generally by postoperative day 3. Lengthening began in our office on postoperative day 5 at an initial distraction rate of 1.0 mm/d for noncongenital LLD femurs and 0.75 mm/d for tibias, as well as, femurs of congenital LLD patients. This rate was further adjusted throughout the distraction phase based upon quality of regenerate formation, as well as, findings on clinical examination. Patients

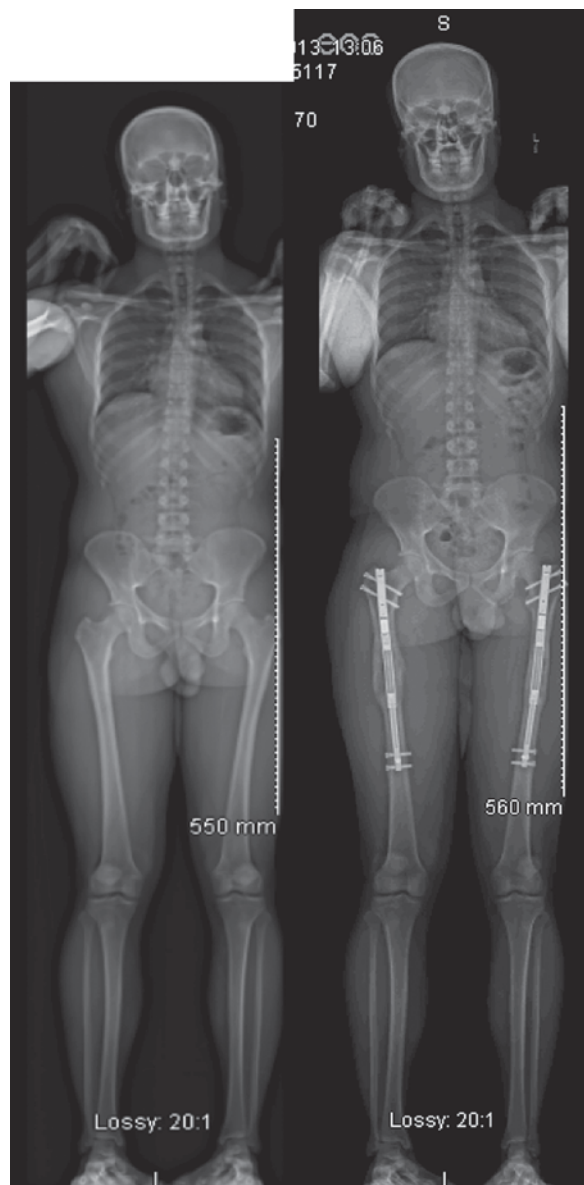


FIGURE 6. EOS scan before (left) and after (right) bilateral femoral lengthening for stature (6.5 cm) in a 26-year-old man.

also began daily physical therapy at our institution beginning on postoperative day 5. Radiographs were obtained 14 days postoperatively and subsequently thereafter at 2-week intervals until the distraction was completed. Once the patient entered the consolidation phase, radiographs were obtained at monthly intervals until healing was confirmed and the patient was advanced to full weight-bearing.

RESULTS

Collectively, the patients in our series achieved a mean lengthening of 4.41 cm (0.5 to 6.5 cm) (Tables 3 and 4). Distraction was performed at a mean rate of 0.83 mm/d (0.5 to 1.11 mm/d), and healing was confirmed at a mean of 125.3 days (52 to 262 d). Complications that were encountered will be discussed within the subsets of patients.

When examined individually, the 23 patients who were treated for congenital limb leg discrepancy gained a mean length of 4.5 cm (0.5 to 6.5 cm), for a mean initial goal of 4.91 cm (1.5 to 6.5 cm). They had a preoperative measured/calculated mean LLD of 6.27 cm (1.5 to 18.2 cm). The distraction rate in congenital LLD patients was 0.80 mm/d (0.5 to 1.07 mm/d), and the mean time for bony healing was 140.7 days (61 to 262 d). Three patients in this group developed deficient regenerate that required a bone grafting procedure that was performed at 230, 249, and 262 days postoperative from the initial surgery.

Five patients who undergoing lengthening of 6 segments did not reach their original goal. One patient was undergoing ipsilateral femoral and tibial lengthening when he developed subluxation at his knee postoperative day 41. This resolved with bracing and physical therapy after his lengthening stopped at both segments. Another patient requested to prematurely stop her femoral distraction to decrease the treatment time, in hope that she could enter the upcoming school year as full weight-bearing. One patient's lengthening stopped 11 mm short of the 6.5-cm goal due to what was thought to be premature consolidation. On removing the nail the internal mechanism was found to have failed.

One patient developed 3 complications starting with a postoperative osteotomy site seroma on postoperative day 27. This was resolved by, incision, drainage, and shortening of the distraction gap using the reverse function of the nail to shorten 18 mm in the operating room (7 min/mm). As the seroma communicated through a fistula it is not clear if this was infected or just contaminated with skin flora. It was treated as a deep infection by 6 weeks of suppressive antibiotics. On postoperative day 40, the same patient sustained a spontaneous proximal intertrochanteric fracture around the implant that required open reduction and internal fixation with a plate. The nail was left in place and lengthening was continued. After 5 cm of lengthening there was only scant bone in the distraction gap and the lengthening was stopped. The distraction gap did not show bone healing and was therefore bone grafted with reamings from the opposite femur. The nail was exchanged for a nontelescopic locking nail by temporarily applying an external fixator in surgery to maintain the length. Length and alignment were maintained, and 3 months later she was found to have completely healed the defect and returned to activities without restriction.

The other deep infection occurred in a patient who accidentally fell asleep with a heating pad positioned over the distal tibial interlocking screws. This caused a second-degree burn and wound breakdown and infection on postoperative day 21. Despite, antibiotic treatment, she continued to drain. The lengthening was completed and on day 37, she was treated by applying an external fixator, removing the Precice and replacing it with an antibiotic-impregnated cement-coated nail. To maintain length an external fixator was applied first and then removed after locking the nail. She proceeded to heal the distraction gap, losing 5 mm of the length gained. She shows no signs of infection. The cement-coated nail was removed on postoperative day 262.

One bilateral femur lengthening patient (who was born with a congenital femoral shortening that had a bad result from a previous shortening of the contralateral femur, required bilateral lengthening to restore the shortened femur to its original length and the congenital femur to match that length) required 2 separate returns to the OR for release of soft-tissue contractures on her congenital short side. She underwent release of the distal fascia lata on postoperative day 23 and then release of the upper fascia lata on day 54. Thereafter, she

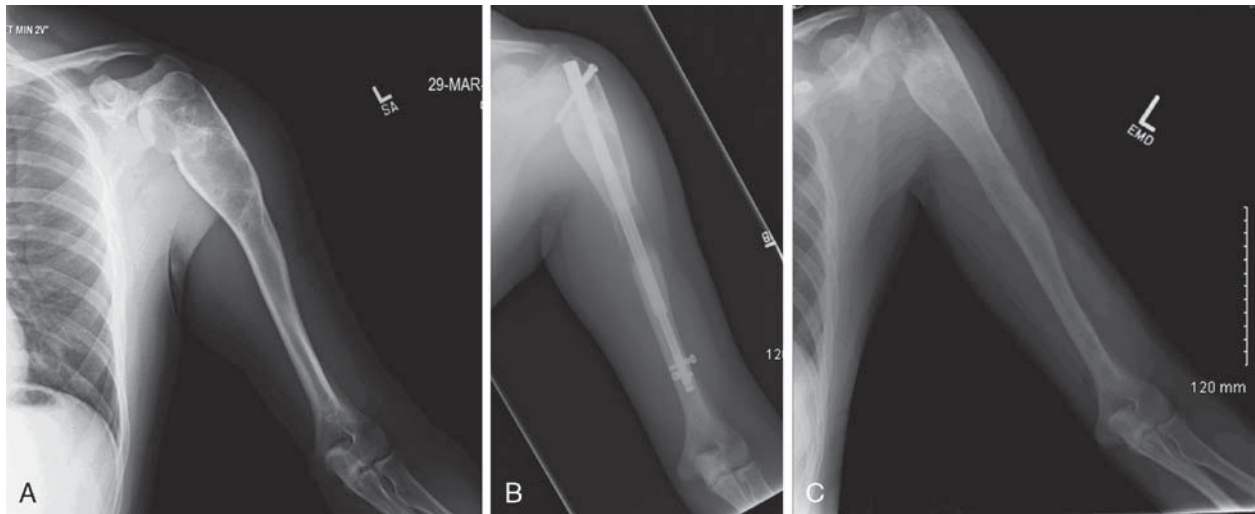


FIGURE 7. A, Unicameral bone cyst of humerus causing growth arrest and arm length difference. B, Lengthening of 6.5 cm of the humerus. C, After removal of nail 1 year later.

was able to complete the entirety of the lengthening uneventfully. Another patient developed symptomatic trochanteric bursitis that required removal of the proximal interlock screws 6 months postoperatively. One patient with tibial hemimelia who had a very hypertrophied fibula and who had a tibia with a history of previous osteomyelitis from an external fixator lengthening has the Precice inserted retrograde into his

hypertrophied fibula with the locking screws going across to the tibia. The proximal interlocking screws started to migrate through his osteoporotic bone late in the distraction phase. As he had a discrepancy >6.5 cm we used this opportunity to exchange his nail for a new Precice and continue to lengthen. We achieved a total of 7.5 cm of lengthening with these 2 nails. The bone healed uneventfully.

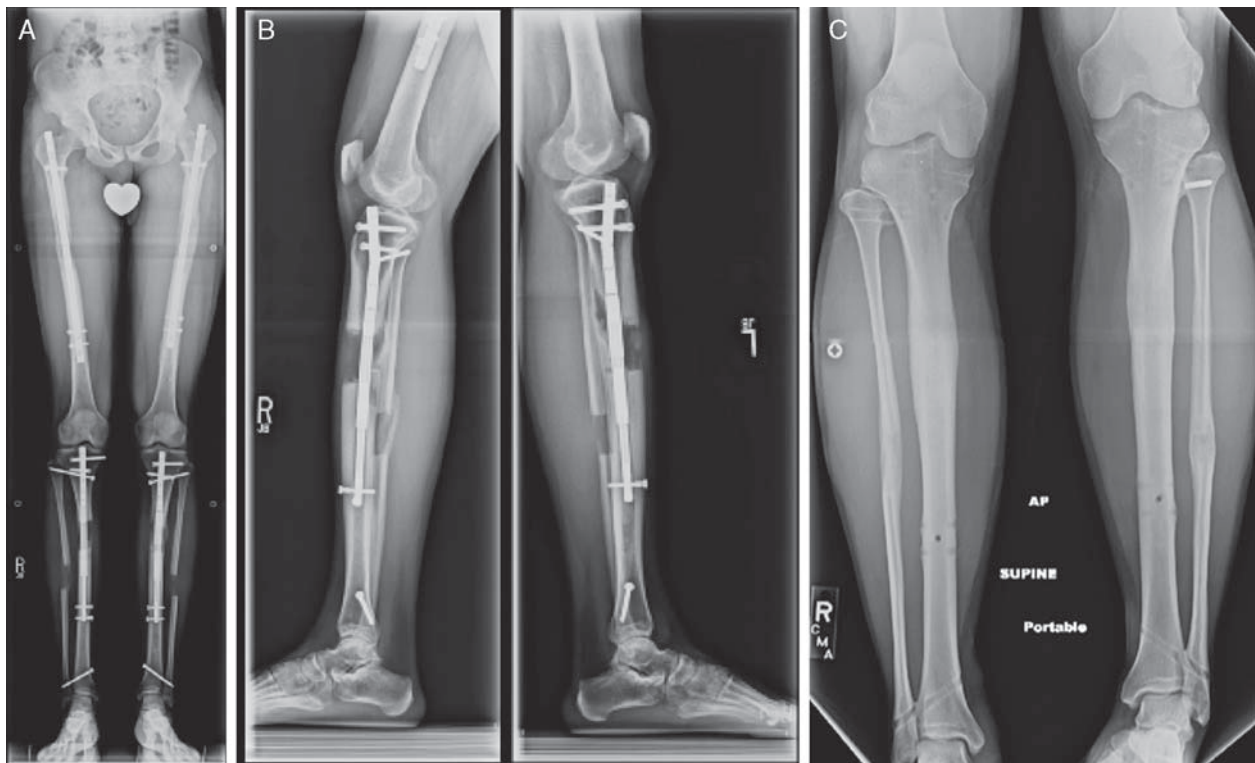


FIGURE 8. A, Anteroposterior radiograph of a 25-year-old man after bilateral Albizzia lengthening of 6 cm in both femurs, undergoing 5 cm lengthening of both tibiae with Precice. Note the inclined proximal and distal screw fixation of the fibula to the tibia. B, Lateral radiographs of both tibiae showing distraction gaps. C, After removal of the tibial rods.

TABLE 1. Nail Location and Direction

Location	No. Patients	No. Nails
Piriformis	25	36
Trochanteric	11	12
Femoral retrograde	5	6
Fibula	1	2
Tibial antegrade	5	6
Tibial retrograde	2	2
Humerus	1	1
Total	NA	65

Four patients treated for developmental LLD gained a mean length of 3.68 cm (1.5 to 6.5 cm). All patients achieved the preoperative goal length without complication. Each patient maintained a mean distraction rate of 1.0 mm/d, and healing was confirmed at 110.3 days postoperatively (90 to 148 d). Six patients treated for posttraumatic LLD achieved a mean length of 3.48 cm (1.7 to 5.0 cm). All patients achieved the preoperative lengthening goal without complication. The mean distraction rate was 0.93 mm/d (0.75 to 1.02 mm/d), and healing was confirmed at 98.5 days postoperatively (52 to 153 d).

Fifteen patients undergoing bilateral lengthening for stature achieved a mean of 4.63 cm (2.7 to 6.5 cm). Seven patients reached their personal preoperative lengthening goals for height augmentation. Eight patients stopped before their personal lengthening goal for a variety of reasons. Three patients stopped lengthening before their personal goals because they needed to get back to work and could not spend the additional time to complete the lengthening and 1 stopped for this reason as well as a developing contracture of the iliotibial band. All the 4 achieved between 4 and 5 cm of lengthening. One teenage patient decided to stop after 2.7 cm, whereas 1 adult patient decided to stop at 4 cm despite both of these patients planning to lengthen 6.5 cm. The decision to stop was personal and not related to pain or dysfunction of the nail. We stopped lengthening in the contralateral limb of the one patient who had unilateral distraction failure to maintain limb lengths. Both achieved between 4.5 and 5.5 cm.

Three nails fractured in 2 patients (Fig. 9). The first patient had progressed to full weight-bearing (without permission). His x-rays at the time showed 2 of 4 cortices healed. The left femoral implant broke and developed a varus-procurvatum deformation. At the time of the fracture the patient was walking up steps on postoperative day 175. He was treated with fixator-assisted closed reduction, followed by removal of the broken hardware, and then exchange nailing with a non-telescopic locking nail. The femur went on to uneventful healing with no loss of length or alignment. The second patient had progressed to full weight-bearing (without permission) and suffered a fracture while walking in the bathroom. The fracture occurred on day 96, when he had 2 of 4 cortices healed. His varus-procurvatum deformation was treated in the same manner as described for the first patient and his left femur healed

TABLE 2. Demographics

Diagnosis	No. Patients	Females	Males
Stature lengthening	15	4	11
Posttraumatic LLD	6	1	5
Congenital LLD	23	14	9
Developmental LLD	4	1	3
Total	48	20	28

TABLE 3. Lengthening Information

All Patients	Range	Mean
Age (y)	10.3-58.4	25.6
Follow-up (mo)	5.0-17.0	9.6
Preoperative LLD (cm)	0.0-18.2	5.35
Preoperative goal (cm)	1.2-6.5	5.00
Mean length achieved (cm)	0.5-6.5	4.41
Distraction rate (mm/d)	0.50-1.11	0.83
Time until fully healed (d)	52.0-262.0	125.3

with no loss of length or alignment. His right femur appeared fully healed at the time. On day 119, his right femur broke reportedly when he was lying in bed. All 4 cortices were healed at the time of the fracture. In all 3 cases the nails broke through the weld of the nail. In 2 through the proximal weld and in 1 through the middle weld. In all 3 there was a visible varus bend present during the distraction. The bend seemed centered at the weld levels.

There were 7 patients in which the mechanism failed to distract. Two of these were due to operator error in applying the ERC device facing the wrong way for a retrograde nail insertion in the femur. Both nails were replaced and lengthening resumed uneventfully. In the other 5 nails the failure of the mechanism was attributed to premature consolidation in one and dense regenerate producing excessive resistance in the other 4. In the premature consolidation case the nail was replaced and a repeat osteotomy performed followed by successful lengthening. The same treatment was carried out for 2 of the dense regenerates with osteotomy at a new level. In 2 of the dense regenerates where the nail would not lengthen further, the patient elected to allow the bones to heal as they were close to the goal of lengthening.

One stature patient developed a deep vein thrombosis 3 days after stopping his oral chemoprophylaxis regimen (Xaralto), and another patient had a superficial infection at an incision site that responded to a short course of oral antibiotics. Two stature patients developed contractures of the iliotibial band during lengthening. One opted to stop the lengthening 1.5 cm short of their preoperative goal but still required a

TABLE 4. Complications

Complications	No. Nails/Events	No. Patients
Implant breakage		
Nail breakage/fatigue failure	3	2
Mechanism failed to lengthen		
Premature consolidation	1	1
Operator error	2	1
Nail failed to distract	0	0
Dense regenerate/high resistance	4	3
Screw cutout/prominent hardware	2	2
Periprosthetic fracture	1	1
Deep infection/implant removal	2	2
Failed regenerate/bone grafting	3	3
Hematoma evacuation	1	1
Soft-tissue contracture release	3	3
Compartment syndrome	0	0
Superficial infection	1	1
Deep vein thrombosis	1	1
Patient request to stop early	7	4
Joint subluxation	2	1
Pain/tightness preventing final goal	12	6
Final length less than preoperative goal	22	13

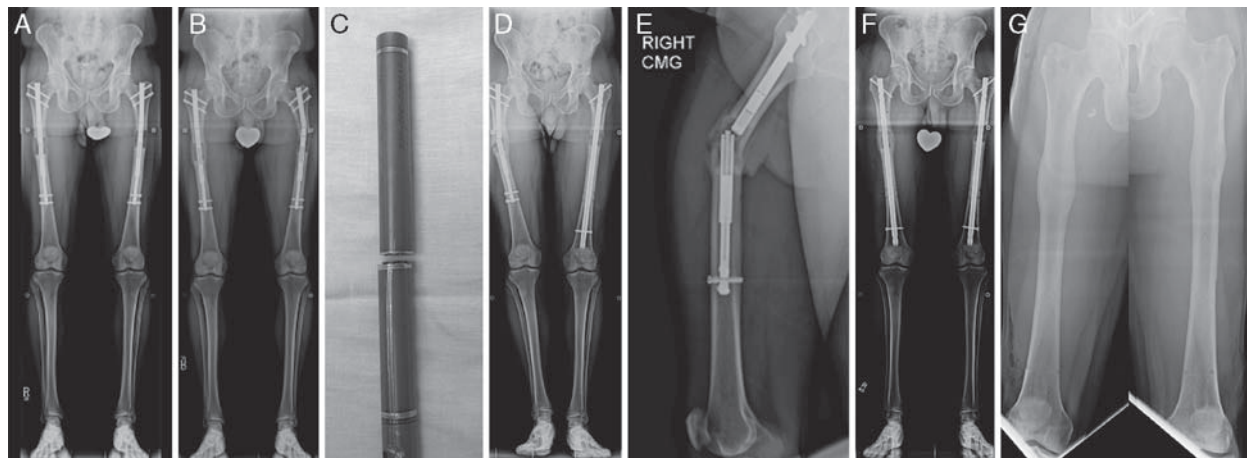


FIGURE 9. A, Bilateral stature lengthening with Precice during the distraction phase. Note the varus bowing bilaterally. B, Fracture of left nail and femur during consolidation phase, after completing a 4-cm lengthening. C, Photograph of the broken nail. The break is through the weld proximal to the mechanism (D&E). Removal of broken nail with fixator assistance and reinsertion with nontelescopic nail on the left. A few weeks later he suffered a fracture of the right femur and nail with severe varus-procurvatum deformity. Note the break is through the weld distal to the mechanism. F, Final radiograph after reinsertion of the femur using fixator assistance to straighten the nail and maintain length. This allowed removal of the broken components. A nontelescopic locking nail was inserted. Both femurs healed without delay and no length or alignment was lost. G, Anteroposterior radiographs after removal of the nails.

release of the iliotibial band. Another patient underwent surgical release of the iliotibial band, and was able to continue lengthening and achieve the target length bilaterally.

DISCUSSION

The goals of implantable distraction nails are to avoid many of the known complications of external fixators while making the process of lengthening more predictable and better tolerated by the patients. Some of the previously designed lengthening nails were fraught with complications. Rate control was a point of concern particularly for the ISKD, the implant for which the term “runaway nail” was coined (Paley D; Unpublished study). The amount of rotation needed to activate the unidirectional lengthening mechanism fell securely within what can be considered normal physiological movement. Many series report problems with implants that lengthened at a rate higher than was desired, and prevention of rapid distraction was difficult and unpredictable at best.

Simpson et al²⁷ reported that 7 of their 33 (21.2%) ISKD nails were classified as runaway implants. Interestingly, a total of 15/33 (45.4%) of their nails experienced rate control complications, with 7 lengthening too quickly, and another 7 being overly difficult to lengthen. Elsewhere in the literature, we can find reports of ISKD nails that lengthened at rates much >1 mm/d, or were classified as runaway nails ranging from 9% (1/11),³² to 18.9% (7/37)³³ to 83.3% (10/12) in the series by Mahboubian and colleagues.^{30,34} The article by Wang and colleagues reports that 5 of their 16 nails lengthened uncontrollably, forcing them to ask these patients to modify their weight-bearing and activity level from week to week based on the rate of distraction of the nail. If it were distracting too slowly, they would be asked to increase their weight-bearing and to become more active, and vice versa (Wang).^{27,29,35} At best, this was a very imperfect way of controlling the rate of distraction of the ISKD. There are additional series that further detail runaway nail rates that range from 9%³² to 20%.^{32,36} The article by the ISKD’s designer³⁷ reviewed his initial series of

20 nails in 18 patients.³⁶ They reported lengthening rates of up to 1.7 mm/d but no mention is made as to how many patients lengthened at such a rapid rate. In an unpublished study by Paley, of 350 ISKD lengthenings, distraction rates of up to 5 mm/d were documented.³⁶

A large majority of patients with runaway nails went on to develop poor regenerate or nonunion at the distraction site. Although the article by Cole and colleagues observed 0 nonunions or patients who required a later bone graft procedure, other articles since document rates of runaway nail patients requiring additional surgery in the form of either bone grafting or exchange nailing that range from 20% (Wang 1/5, 5/7,³³ to 6/7²⁷) to 86%.²⁹

Certainly, poor regenerate formation/nonunion is not exclusive to intramedullary nails that fail to maintain safe rate control, but rather, this remains a well-known complication for all limb lengthening procedures.¹ Although only 1/5 of the runaway nails in the article by Wang and colleagues required later bone grafting, a total of 6 of their 16 ISKDs (37.5%) required an additional surgery to treat poor regenerate or nonunion.²⁹ Simpson et al²⁷ needed to treat only 6/8 (75%) of his runaway nails with additional surgery, although, a total of 8/33 (24.2%) nails ultimately required this approach. Five of the 7 (71.4%) runaway nails in Kenaway et al’s³³ series required bone graft and/or exchange nailing, along with an additional 3 nails that similarly developed deficient bone healing, for a total of 8/37 (21.6%). Singh et al²² reported that 3/24 (12.5%) of their Fitbone nail segments required later bone grafting, and Baumgart et al³⁶ saw that 1/12 (8.3%) Fitbone segments need additional surgery to achieve adequate healing.

The paper by Kenaway et al²⁸ found a significant association between poor regenerate and age of patients >30, total lengthening >4 cm, smoking, and a distraction rate >1.5 mm/d.

One risk that has been reported to be a predisposing factor to poor regenerate is a distraction rate >1.5 mm/d.²⁸ This is entirely avoided with the Precice nail. In comparison with results listed above, only 3 of our 65 implant segments went on to develop poor regenerate or nonunion that necessitated an additional bone grafting surgery. Uncontrolled distraction was not seen in any of our cases.

In this series the treatment including the rate was tailored to each patient; slowing the rate when there appeared to be deficient regenerate or soft-tissue tightness, and increasing the rate in situations where there was exuberant callus at risk of premature consolidation. Because of the reversibility the Precice permits dynamization by cycles of daily compression-distraction (1 to 2 mm each) to stimulate consolidation. This was used in a few cases that showed slow healing. In 1 case that initially looked like it would require bone grafting the distraction gap united without surgery.

Another well-reported problem with implantable lengthening nails is difficulty with distraction. Kubiak and colleagues attributed this to impingement and friction secondary to a straight nail attempting to lengthen a curved femur, as well as, compressive forces caused by the soft tissues that are substantial enough to limit lengthening. This complication is still the most frequent one with the Albizzia nail. Failure to distract can be related to wear of the teeth of the internal ratchet gear or due to the inability of the patient to turn the limb the full 20 degrees due to pain. Similarly with the ISKD, some patients have too much pain to rotate the femur the 3 to 9 degrees needed. Manipulation by the surgeon in the office to manipulation under epidural or other anesthesia has been used to treat this problem. Botox injection into the quadriceps to reduce muscle spasm is also useful. Incidence of failure to distract with ISKD varies, from 0%³⁶ to 64%³² of whom 6/7 of the patients in that series required a return to the OR.³⁶ Similarly, the Simpson et al²⁷ series had a rate of 24.2% (8/33) of ISKD nails that were difficult to distract, and 75% (6/8) of those needed a return to the OR.

In our series we had 7 cases of failure to distract. One of these occurred due to user error. The nail was introduced retrograde into a femur for lengthening and deformity correction. The ERC device was applied facing distally causing compression instead of distraction. This led to breakage of the mechanism at the junction of the coupling of the gears to the drive shaft. The nail was exchanged and the lengthening proceeded normally once the ERC device was applied correctly. In 1 bilateral case, the femur failed to continue to lengthen after about 4.5 cm. The lengthening was stopped. When the nails were extracted 1 year later the mechanism was found to have failed. This probably occurred due to excessive resistance from abundant callus. One case of premature consolidation and 2 cases of dense regenerate also had a failed mechanism. It is difficult to know if this failure of the mechanism occurred after repeated lengthening attempts against the force of a prematurely consolidated bone or did the premature consolidation result from failure of the nail mechanism to continue to distract against increasing resistance.

Mechanical failure of other implantable nails can be divided into 2 groups: mechanical failure of the distraction mechanism and breakage of the integrity of the nail itself. In the Baumgart et al²¹ series of 12 cases, 2 patients required reoperation for the failure of mechanism. There were no nail breakages in this series. In a Fitbone series of 24 nails, 2 patients had to have exchange nails to larger diameter Fitbone nails as the gears were too weak for distraction. Both these patients had congenital deformities.²² Another Fitbone cohort of 8 patients reported 1 mechanism failure and 1 nail breakage; both were also congenital etiologies.²³ The ISKD initial series (20 nails) reported 2 hardware failures; both nails broke with patients fully weight-bearing and at the junction of the proximal and distal components. Design changes were made in the nail and authors claimed no further breakages. This further stresses the importance of in vivo analysis of these devices and

appropriate engineering adjustments to improve product design. No mention of mechanism failure was noted in this series.³⁷ Another review of 57 ISKD nails revealed no nail breakages, however, 3 failures of the lengthening mechanism. One requiring an exchange nail with an examination of the failed nail showing a jammed ratchet mechanism. The other 2 nails required manipulation another anesthesia, however, 1 nail acutely lengthened 3 cm instead of 3 mm despite external monitoring; once again illustrating the unpredictability of these nails.³³ In the largest ISKD series of 242 devices, 15 (6.2%) experienced mechanical failure. Ten of these failures were nail fractures, 2 of which were in the same patient undergoing stature lengthening. Most fractures were in the male component, however, other areas of nail were prone to failure as well. The remaining 5 nails failed at the lengthening mechanism; 2 of which failed due to assembly error.³⁶ Ensuring the functionality of the nail during surgery, as in our surgical protocol would circumvent these types of complications. In 41 Albizzia nail insertions, 3 failures were related to the distraction mechanism and 1 nail fracture, all required reoperation (Guichet et al).³⁷

In this series there were 3 breakages of the integrity of the nail itself. All 3 occurred in bilateral femoral lengthening for stature patients who were fully weight-bearing (without permission) early in the consolidation phase. All 3 occurred through the welds of the nail and all 3 showed preoperative varus bending of the nail. As there are no other published reports of Precice lengthenings, one cannot compare this complication to other series. However, anecdotal reports have arisen of 3 fractures at other centers also through the welds. In all but one case they occurred in bilateral lengthening cases. The weld is a weak point in the Precice 1 nail. This weakness is protected in unilateral cases by having 1 good leg to stand on and thus being able to unload the other leg with crutches. In bilateral cases unless the patient is only using a wheelchair they cannot really unload the femur with crutches or a walker.

Achieving the goal of lengthening is dependent on many factors. These include the reasonableness of the goal of lengthening relative to the pathology, obstacles, and complications that develop during lengthening that recommend against continued distraction, pain, length distraction time affecting time off school and work and/or school or work deadlines (such as timing of start of school year), economic, social, and family reasons. Many of these have nothing to do with the device, but rather with the slow, protracted lengthening process, and the need for frequent follow-up, physical therapy, daily pain medicine, etc. However, the device does impact the ability to achieve the goal in some cases. For example, the runaway nail scenario can lead to subluxation of a joint or nerve injury or failure of bone formation, etc. all of which will affect the decision to continue lengthening or not.

Among 10 patients (24 nails) with the Fitbone device, 2 patients (20%) did not reach anticipated length due to restricted knee movement. Both these patients were undergoing stature lengthening and had femoral and tibial lengthening.²² In a smaller series (8 patients) using the same device, they achieved 93% (83% to 100%) planned length. However, 2 of the 8 patients were eliminated from this analysis due to nail failure.²³

Using the ISKD nail lengthening of 33 limbs resulted in 32 achieving desired goals. However, 8 patients (8 limbs) required additional procedures (manipulation, fixator-assisted) to achieve this due to slow or no progression of distraction.²⁷ Baumgart and colleague's cohort of 12 patients attained complete length objectives in all patients. Interestingly, all

these patients received unilateral lengthening, which eliminates many factors that may cause premature termination. Similarly to our series where most of these terminations were in our bilateral group, especially true with our stature lengthening patients with very subjective goals. Nevertheless, internal devices in previous and in our current series seem to have a good track record for obtaining desired lengths.

Pain is an important consideration with every lengthening method. Pain is an expected part of lengthening. The degree of pain does vary between external and internal fixation methods. Pin sites and pin infections as well as tethering of muscles and other soft tissues are believed to be a major cause of pain during lengthening with external fixation. As all of these are absent with implantable devices, the pain is related to stability, rate of distraction, physical therapy, and stretch of soft tissues. Although it is not possible to eliminate stretch, control of rate and stability of fixation is device dependent. Friction may also play a part and can be limited by the, type of reamers used (straight vs. flexible), amount of overreaming, as well as by the level of osteotomy (at apex of curvature of femur; leaving as short an amount of nail to drag on the moving segment).

Pain as already notes was a major factor with the Albizzia and ISKD. Both of these devices rotate through the callus. Such rotation leads to friction and muscle spasm pain. This type of pain has been notably absent from reports on the Fitbone and from the experience in this study.

Using devices that require no rotation like the motorized Fitbone, here was minimal or no pain on lengthening (Singh et al).²² However, of the 10 patients, who had 24 implants, only 2 achieved 60 mm. The rest were between 27 and 50 mm, with a mean of 40 mm/nail. In contrast, of the 31 patients using the Albizzia nail all experienced discomfort or pain during lengthening. Twelve patients (39%) required readmission to perform ratcheting under general anesthetic.³⁸ Our Precice patients seem to have minimal to no pain during lengthening. Also, they are generally admitted on average 2 to 3 days before discharge on oral pain medications. Furthermore, small incisions are used to insert device limiting soft-tissue damage and scar formation.

Device evolution is part of progress. The senior author (DP) had the privilege of being involved in the development of 4 of the implantable lengthening nails that are used today. The senior author was a consultant to the Medinov of the Lander group (Nancy, France) regarding the Albizzia nail and designed and first implanted their tibial nail (femoral nail developed by Guichet and Grammont). This non-FDA-approved device was used as a compassionate use device in the United States in the mid 1990s by several surgeons. This experience uncovered an essential design problem that led to frequent failure due to wear ratchet gear. Hardening the metal used for this part solved this problem. The current Albizzia has also been strengthened to use cobalt chrome instead of stainless steel to permit greater weight-bearing in bilateral lengthening cases. It is currently marketed as either the Guichet nail or Betzbone device by these 2 surgeons, respectively. Despite the increased strength of cobalt chrome there continue to be fatigue failures of the stainless steel screws due to excessive loading, as a reminder that unprotected weight-bearing until distraction gap consolidation is not a good idea. The senior author was also the first user of the ISKD device after its inventor Dean Cole, MD. As a consultant to Orthofix at that time, the company was advised in the first year of ISKD device use (2001 to 2002), that the lack of rate control was a major problem. Certainly many of the problems of not being able to get the nail going which plagued the Albizzia, were solved by

the smaller degree of rotation required to actuate the lengthening. These were replaced by the “runaway” phenomenon of too rapid distraction. Although surgeons worked around this problem by decreasing patient activity, using bulky braces such as hip-knee-ankle-foot orthotics, no fix to the problem was offered by the company. The device was finally withdrawn from the market in 2011. It is unknown whether an ISKD2 with better rate control will be available in the future. The senior author also worked with Arnaud Soubieran while he was developing the Phenix nail. There were many trials and tribulation with the initial mechanism. After Soubieran solved most of these, the senior author introduced this nail to Smith and Nephew and worked briefly as a consultant for them on this device. In 2010, the senior author elected to leave the Smith and Nephew team and to become part of the Precice nail development team headed by Stuart Green, MD.

Between December 1, 2011 and November 1, 2013, 155 Precice nails were inserted into 100 patients at the Paley Institute. In addition to the complications listed in this study of the first 65 Precice nails, there have been no more nail breakages through the welds (partly due to greater vigilance in restricting weight-bearing in bilateral femoral lengthening patients). Therefore, the total number of nail breakages for the first 155 Precice lengthenings is 3. In total, there have been 7 mechanisms of 155 that failed to lengthen, 2 due to operator error by the surgeon’s team in applying the ERC device the wrong way and 5 after meeting excess resistance from the callus. There was also 1 femur fracture that occurred after the study group was closed. The fracture was through a distal AP locking screw at the end of distraction that occurred during physical therapy (the smaller end of the nail bent about 10 degrees at the time of fracture). The distal end of the nail offers 3 locking holes; 2 medial-lateral, and 1 AP. In the femur we intentionally nail short to avoid issues with the femoral bow. This creates a stress riser in the mid femur at the end of the nail. That stress riser is increased by an AP drill hole and screw. Although we only saw this complication in 1 patient, we no longer use the AP locking screw for femoral lengthening. We also frequently avoid this screw in the tibia, as the screw head is so subcutaneous and at risk of being exposed if the wound breaks down. A case in point is the 1 patient in the study series who suffered an accidentally self-induced burn over this locking screw by a heating pad, leading to wound breakdown and a deep infection.

Although the reported study was conducted as a retrospective review, it represents a consecutive series with no cases eliminated. As one of the company consultants, the senior author kept Ellipse Technologies abreast of all problems and complications with the Precice as they occurred. The company acted both responsively and responsibly as the complications of failure to distract in the face of rapid consolidation of callus, and fractures of the nail occurred. Although infrequent in occurrence, this study identified 2 potential failure modes with the first version of the Precice nail (which I will herein call Precice 1 or P1): the junction of the gears to the lead screw, and, the welds of the nail on either side of the drive mechanism. Such device failures were clearly less common than documented failures with the only other FDA-approved cleared device, the ISKD.³⁶ Nevertheless, at the advice of and in consultation with the senior author, Ellipse Technologies immediately began work to design a new non-modular nail that had a stronger gear to lead screw connection and to eliminate the welds in the outer tube of the nail. The gear-lead screw correction was implemented in May 2013. The 1-piece outer tube with no welds required FDA clearance




FIGURE 10. The Precice 1 nail with its 3 welds is shown on the left. The Precice 2 nail which has no welds is shown on the right.

which was obtained in October 2013. The Precice 2 (P2) was first used in the United States in November 2013 (Fig. 10). The P2 is at least 2 times stronger in bending fatigue strength and has a 3 times stronger coupling between the gears and lead screw. The P2 also has greater distraction capacity (stroke length) and is available in 50- and 80-mm stroke lengths. The P2 is also available in a smaller outer diameter (8.5 mm). To achieve these strength gains, modularity is not a feature of the P2. In the P2 one has to select the type of insertion locking end (piriformis, trochanteric, retrograde, or tibial) and the length of the nail in advance. With the exception of attaching the insertion end to the nail, the procedure for insertion of the nail as well as its indications are the same as for the P1. The greater stroke length, while allowing for greater distraction amount must be guided by the usual parameters that guide responsible continued lengthening: pain, bone formation, joint range of motion and stability, and neurological status.

The future for noninvasively adjusted limb lengthening devices is very exciting. Future innovation will likely produce a bone transport nail to treat bone defects, limb lengthening plate for children with open growth plates, and gradual deformity correction plates. Miniaturization and new mechanisms will allow greater application of such technology. Adjustable nails could eventually replace simple locking nails for trauma, allowing adjustability of length postoperatively.

The same technology as applied to prostheses will also find its way from growing prostheses for bone tumors in children to adjustable length joint replacement for the treatment of arthritis.

REFERENCES

- Codivilla A. On the means of lengthening, in the lower limbs, the muscles and tissues, which are shortened through deformity. *J Bone Joint Surg Am.* 1905;s2-2:353–369.
- Putti V. The operative lengthening of the femur. *JAMA.* 1921;77:934–935.
- Allan F. Bone lengthening. *J Bone Joint Surg Br.* 1948;30:490–505.
- Abbott L. The operative lengthening of the tibia and fibula. *J Bone Joint Surg Am.* 1927;9:128–152.
- Dickson F, Diveley R. A new apparatus for the lengthening of legs. *J Bone Joint Surg Am.* 1932;14:194–196.
- Bosworth D. Skeletal distraction of the tibia. *Surg Gynecol Obstet.* 1938;66:912–924.
- Green SA. Complications of external skeletal fixation. *Clin Orthop Relat Res.* 1983;180:109–116.
- Paley D. Current techniques of limb lengthening. *J Pediatr Orthop.* 1988;8:73–92.
- Paley D. Problems, obstacles, and complications of limb lengthening by the Ilizarov technique. *Clin Orthop Rel Res.* 1990;250:81–104.
- Herzenberg JE, Scheufele LL, Paley D, et al. Knee range of motion in isolated femoral lengthening. *Clin Orthop Rel Res.* 1994;301:49–54.
- Stanitski DF, Bullard M, Armstrong P, et al. Results of femoral lengthening using the Ilizarov technique. *J Pediatr Orthop.* 1995;15:224–231.
- Simpson AH, Kenwright J. Fracture after distraction osteogenesis. *J Bone Joint Surg Br.* 2000;82:659–665.
- Danziger MB, Kumar A, DeWeese J. Fractures after femoral lengthening using the Ilizarov method. *J Pediatr Orthop.* 1995;15:220–223.
- Baumann F, Harms J. The extension nail. A new method for lengthening of the femur and tibia. *Arch Orthop UnfallChir.* 1977;90:139–146.
- Bliskunov AI. Intramedullary distraction of the femur. Preliminary report. *Orthop Travmatol Protez.* 1983;10:59–62.
- Götz J, Schellmann WD. Continuous lengthening of the femur with intramedullary stabilization. *Arch Orthop UnfallChir.* 1975;82:305–310.
- Schollner D. New ways of operating to lengthen the femur. *Z Orthop.* 1972;110:971–974.
- Witt AN, Jäger M, Hilderbrandt JJ. An implantable femur distractor for operative leg lengthening. *Arch Orthop Trauma Surg.* 1978;92:291–296.
- Witt AN, Jäger M. Results of animal experiments with an implantable femur distractor for operative leg lengthening. *Arch Orthop Unfallchir.* 1977;88:273–279.
- Bliskunov AI. Udlineniie bedra intrameduliarnymi distraktorami (Lengthening of the femur by the intramedullary distractors) II Sb. nauch.rabot TSITO: “Meditsinskaia reabilitatsiia bolnykh s perelomami kostei i ortopedicheskimi zabolevaniiami.” Moskva. 1983. No26. C.36–41.
- Baumgart R, Betz A, Schweiberer L. A fully implantable motorized intramedullary nail for limb lengthening and bone transport. *Clin Orthop Rel Res.* 1997;343:135–143.

22. Singh S, Lahiri A, Iqbal M. The results of limb lengthening by callus distraction using an extending intramedullary nail (Fitbone) in non-traumatic disorders. *J Bone Joint Surg Br.* 2006;88:938–942.
23. Krieg AH, Speth BM, Foster BK. Leg lengthening with a motorized nail in adolescents: an alternative to external fixators? *Clin Orthop Rel Res.* 2008;466:189–197.
24. Young N, Bell DF, Anthony A. Pediatric pain patterns during Ilizarov treatment of limb length discrepancy and angular deformity. *J Pediatr Orthop.* 1994;14:352–357.
25. Garcia-Ciembrelo E, Olsen B, Ruiz-Yague M, et al. Ilizarov technique: results and difficulties. *Clin Orthop Relat Res.* 1992;283:116–123.
26. Guichet JM, Casar RS. Mechanical characterization of a totally implantable gradual elongation nail. *Clin Orthop Relat Res.* 1997;337:281–290.
27. Simpson AH, Shalaby H, Keenan G. Femoral lengthening with the intramedullary skeletal kinetic distractor. *J Bone Joint Surg Br.* 2009;91:955–961.
28. Kenawey M, Krettek C, Lioudakis E, et al. Insufficient bone regenerate after intramedullary femoral lengthening: risk factors and classification system. *Clin Orthop Rel Res.* 2010;469:264–273.
29. Ji B, Jiang G, Fu J, et al. Why high frequency of distraction improved the bone formation in distraction osteogenesis? *Med Hypotheses.* 2010;74:871–873.
30. Mahboubian S, Seah M, Fragomen AT, et al. Femoral lengthening with lengthening over a nail has fewer complications than intramedullary skeletal kinetic distraction. *Clin Orthop Rel Res.* 2012;470:1221–1231.
31. Cheung KM, Cheung JP, Samartzis D, et al. Magnetically controlled growing rods for severe spinal curvature in young children: a prospective case series. *Lancet.* 2012;379:1967–1974.
32. Kubiak E, Strauss E, Grant A, et al. Early complications encountered using a self-lengthening intramedullary nail for the correction of limb length inequality. *Jt Dis Relat Surg.* 2007;18:52–57.
33. Kenawey M, Krettek C, Lioudakis E, et al. Leg lengthening using intramedullary skeletal distractor: results of 57 consecutive applications. *Injury.* 2011;42:150–155.
34. Hankmeier S, Pape HC, Gosling T, et al. Improved comfort in lower limb lengthening with the intramedullary skeletal kinetic distractor. Principles and preliminary clinical experiences. *Arch Orthop Trauma Surg.* 2004;124:129–133.
35. Wang K, Edward E. Intramedullary skeletal kinetic distractor in the treatment of leg length discrepancy—a review of 16 cases and analysis of complications. *J Orthop Trauma.* 2012;26:e138–e144.
36. Burghardt RD, Herzenberg JE, Specht SC, et al. Mechanical failure of the intramedullary skeletal distractor in limb lengthening. *J Bone Joint Surg Br.* 2011;93:639–643.
37. Cole JD, Justin D, Kasparis T, et al. The intramedullary skeletal kinetic distractor (ISKD): first clinical results of a new intramedullary nail for lengthening of the femur and tibia. *Injury.* 2001;32(suppl 4):SD129–SD139.
38. Guichet JM, Deromedis B, Donnan LT, et al. Gradual femoral lengthening with the Albizzia nail. *J Bone Joint Surg Am.* 2003;85:838–848.