

31

Principles of Foot Deformity Correction: Ilizarov Technique

DROR PALEY

The Ilizarov technique lends itself well to correction of foot deformities because of the three-dimensional nature of the foot and of the apparatus. The two approaches to the correction of foot deformities are (1) soft tissue distraction of the deformity and (2) distraction of an osteotomy. In the former, the deformity is corrected by eliminating pre-existing contractures and by distracting across joints in an attempt to bring them into a new congruous relationship to a plantigrade position.^{3, 5, 8, 18} In the second, the distraction occurs through osteotomies, regenerating new bone and eliminating deformities by opening wedge-type corrections.^{7, 8, 15, 18} The joints remain undisturbed with osteotomy distraction techniques. The decision as to which approach to use depends on several factors: (1) age, (2) the presence or absence of fixed bony deformities, and (3) the stiffness of the deformity.

The decision for nonosteotomy treatment depends primarily on the age of the patient. Essentially, any deformity can be treated without osteotomy in patients younger than 8 years of age. In patients older than 8, the presence of fixed bony deformities is generally a contraindication to nonosteotomy treatment. An exception to this rule is when the joints to be distracted are so stiff that there is significant risk of physeal disruption rather than joint distraction. In these cases, osteotomy treatment may be preferable. The indications for nonosteotomy treatment are similar to those for soft tissue release by conventional means.¹⁷ Soft tissue release relies on biologic plasticity and remodeling of cartilaginous bones. Dis-

traction is thought to reshape bones by activation of the circumferential physis of these bones.¹⁵ Nonosteotomy treatment may still be considered in the presence of fixed bony deformity if limited arthrodeses are planned to maintain the correction that is obtained by joint distraction. This reduces the amount of bone that needs to be resected at the time of arthrodesis.

Therefore, osteotomy treatment is indicated for fixed bony deformity in patients older than 8 years of age in whom sufficient incongruity of the joints, which could not be expected to remodel, would result from the soft tissue distraction or release. This treatment may also be indicated in patients with neuromuscular imbalance in whom soft tissue correction would obtain but not maintain the correction. An osteotomy in such patients provides a lasting correction through bone instead of joints.

NONOSTEOTOMY FOOT DEFORMITY CORRECTION

There are two approaches to the correction of contractures by the Ilizarov method: constrained and unconstrained. In the constrained system, it is necessary to find the axis of rotation of the joint contracture and to perform the correction around this axis. In the unconstrained system, one allows the contracture to correct itself around soft tissue hinges and natural axes of rotation of joints.

The advantage of the constrained system is that the uniaxial hinge allows disconnection of

the distraction rod with active and passive range of motion of the joint being treated. With the unconstrained system, the fixation is relatively unstable the moment the distraction rods are removed. Therefore, the system must remain under distraction at all times, without any joint mobilization. The advantage of the unconstrained system is that it is simpler to apply and allows for errors in application. The constrained system, on the other hand, is very precise, and the hinges must be aligned to the joint axis within a narrow range of tolerance to avoid jamming of the joint. Incorrect hinge placement can also inadvertently lead to joint compression. The unconstrained method is advantageous for the treatment of the multiple foot joints that do not have a known simple single axis of rotation and is less advantageous for the treatment of joints such as the ankle, which do have an easy-to-locate axis.

Equinus Deformity

The ankle joint lends itself well to both constrained and unconstrained methods of

treatment. The axis of rotation of the ankle lies approximately at the level of the lateral process of the ankle. Its axis extends laterally through the tip of the lateral malleolus and medially below the tip of the medial malleolus. The ankle joint surface has the curvature of a frustum, which is a section of a cone. The center of rotation of a cone is not parallel to its edges. Therefore, the center of rotation of the ankle is not parallel to the tibial plafond. Rather, the center of rotation is higher on the medial side than on the lateral side. This is easily remembered according to the levels of the two malleoli.

Constrained Method (Figs. 31-1 and 31-2)

The image intensifier is used to locate the axis of rotation of the ankle. Preoperatively, Mose circles are applied to a true lateral image of the ankle to identify the level of the axis of rotation. The center is usually within the lateral process of the ankle. The image intensifier is used to obtain a true lateral image of the ankle such that the lateral malleolus is centered

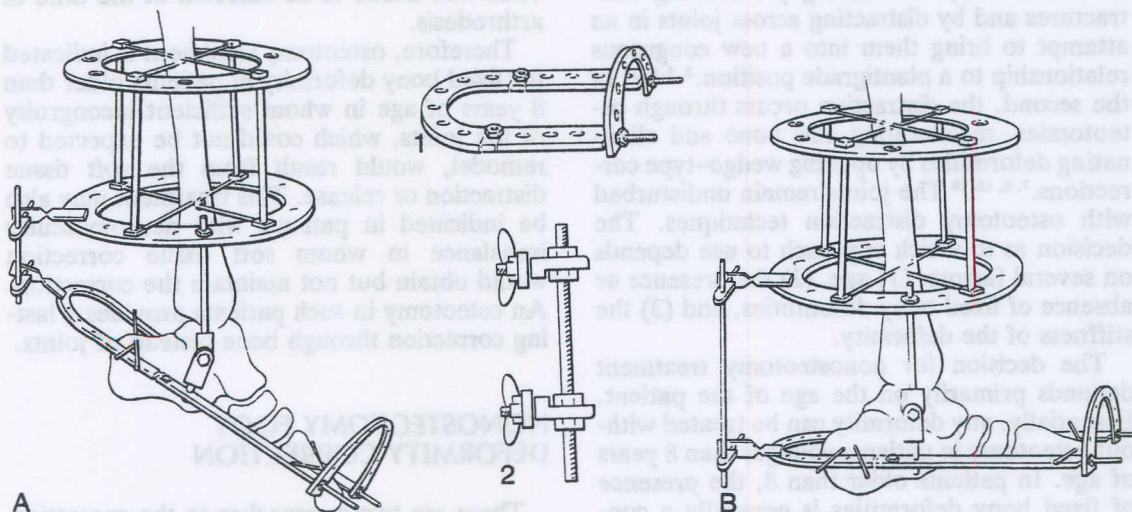


FIGURE 31-1. Correction of ankle equinus deformity: constrained method. (A), The apparatus is shown applied to the tibia and foot. The apparatus consists of a two-ring frame on the tibia and a foot ring on the foot. The two are articulated using a threaded rod and hinges. The hinges are applied medially and laterally so that they overlie the center of rotation of the ankle. The ankle joint can be distracted apart by the threaded rod end of the hinge so as to avoid crushing the joint cartilage. The foot ring consists of a half-ring and two plates with threaded rod extensions connected by an anterior half-ring perpendicular to the rest (inset 1). The distraction apparatus posteriorly consists of two twisted plates with a threaded rod distracting between them connected by a post or hinge. The post or hinge is fixed to the twisted plate with wing nuts (inset 2). This allows removal and reapplication with ease. Two wires are fixed on each of the tibial rings, with an important olive wire placed anteriorly. Two wires are fixed to the calcaneus and two are fixed to the metatarsals. (B), The distraction is performed at 1 to 2 mm/day to the patient's tolerance level. Overcorrection of the equinus is achieved. The patient maintains range of motion during the distraction.

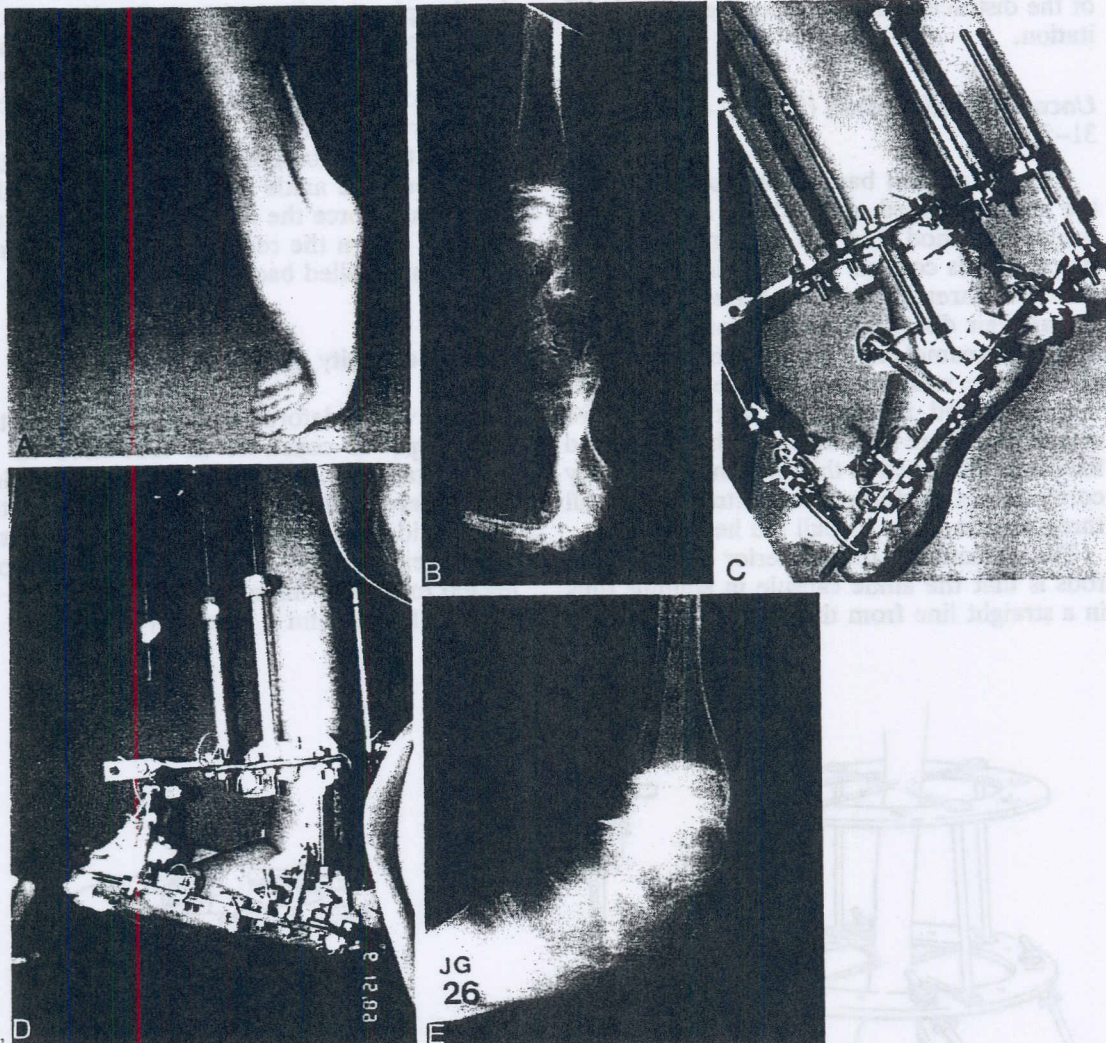


FIGURE 31-2. (A and B), Lateral photograph and radiograph of the ankle before correction. (C and D), The apparatus is shown from the lateral view during correction and at the end of overcorrection. Note that in this example, a wire was inserted across the axis of rotation of the ankle joint and connected to the hinges. This is another modification of the constrained technique. (E), The lateral radiograph after correction. (Courtesy of Dror Paley, M.D.)

over the midlateral tibia. A wire is used to point to the center of rotation. Once the wire overlaps the region of the lateral process, this spot is marked on the skin. The same process should be repeated for both the medial and lateral sides. The image intensifier must be perpendicular to the tibia.

Step 1. Apply a preconstructed two-level frame to the tibia. Use four wires to fix the tibial frame to the leg. For equinus correction, use one anterior olive medial-face wire on the distal of the two rings and one transverse wire on this ring.

Step 2. Suspend hinges from threaded rods off the distal tibial ring. Overlap the hinge with the center of rotation of the ankle joint.

Step 3. Apply the foot frame to the hinges. Adjust the foot frame so that it is parallel to the plantar aspect of the foot. This can be done by placing a board on the plantar aspect of the foot and making sure the foot frame is parallel to the board. A distraction rod off two pivot points such as a twisted plate is connected posteriorly in the central hole between the two hinges. Wing nuts are used to connect the posts at either end of the distraction rod. This allows quick application and removal. The

patient can combine distraction with removal of the distraction rod for exercise and rehabilitation.

Unconstrained Method (Figs. 31-3 to 31-5)

The same tibial base of fixation is used for the unconstrained method as for the constrained method, but the foot frame is much simpler. This consists of a half-ring suspended off three threaded rods that are locked by a nut at their distal end and by conical washers at their proximal end. The maximum posterior tilt of these washers is 7.5 degrees. The half-ring is locked in place at that angle. Two smooth wires are inserted through the heel and fixed and tensioned to this half-ring. Deformity correction is performed by distraction on all three rods in order to pull the heel distally.

The reason for the posterior tilt of these rods is that the ankle capsule in equinus runs in a straight line from the back of the talus to

the posterior lip of the tibia. When the foot is in the plantigrade position, the line of the ankle capsule is tilted 5 to 7 degrees posteriorly. This is because the posterior lip of the talus protrudes posterior to that of the tibia. If the rods were not tilted back but were parallel to the tibia, distraction along that line would pull the ankle capsule directly distally. This would force the talus forward, out of the mortise. When the rods are tilted posteriorly, the talus is pulled back into the mortise.

Varus Deformity (Figs. 31-6 and 31-7)

Heel varus deformity is corrected by the same type of construct as that used in an unconstrained correction of equinus deformity. The difference is that an olive is used on the medial side. The threaded rods are connected via hinges. The posterior threaded rod is connected to a two-, three-, or four-hole hinge so that the hinge point is proximal to the level of

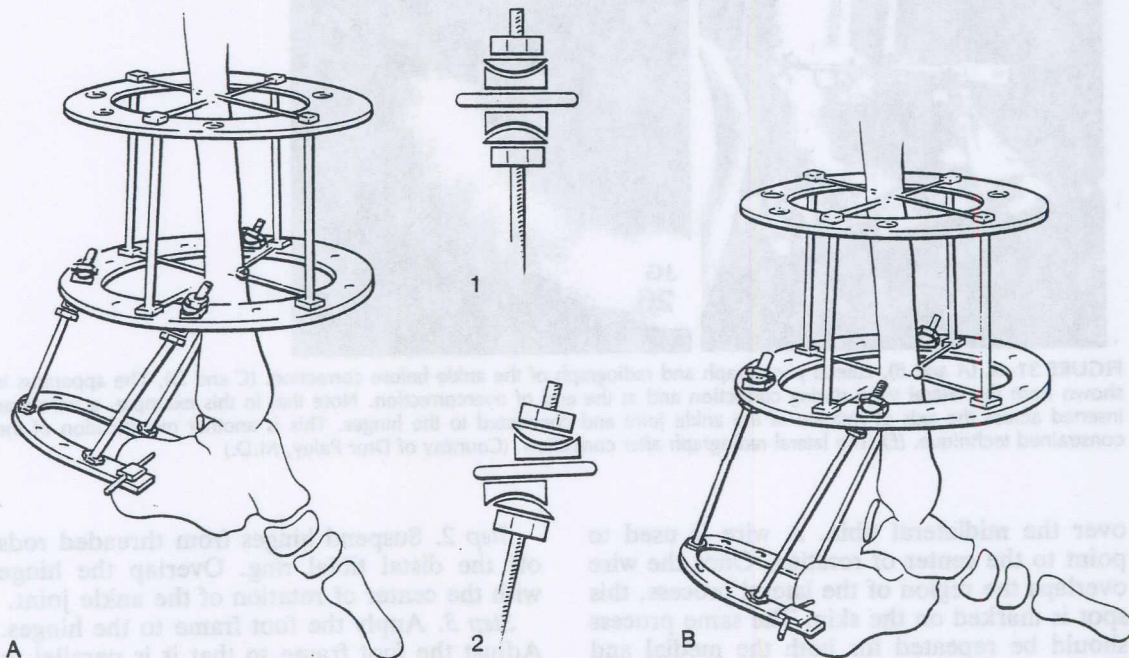


FIGURE 31-3. Correction of ankle equinus deformity: unconstrained method. (A), The unconstrained apparatus consists of two rings in the tibia and a half-ring in the heel. One- or two-wire fixation is used in the heel, and two wires are used on each of the tibial rings, with an olive anteriorly on the distal ring. Three threaded rods are used to suspend the half-ring. These are fixed with nuts directly to the half-ring but are fixed with interposing conical washers on the distal tibial ring. This allows the half ring to be tilted posteriorly by approximately 7 degrees (insets 1 and 2). (B), At the end of the correction, the foot has been distracted downward and posteriorly at a 7-degree tilt. This keeps the ankle in the mortise. Notice that the ankle capsule in the uncorrected position runs vertically from the posterior lip of the tibia to the back of the talus. In the corrected position, the ankle capsule is oriented with a posterior slope to it. This slope parallels the 7-degree direction of distraction. Note also that the ankle and subtalar joints are overdistracted. This method does not allow removal of the rods for exercise of the joints; therefore, the overdistracted is important in maintaining a loose joint.

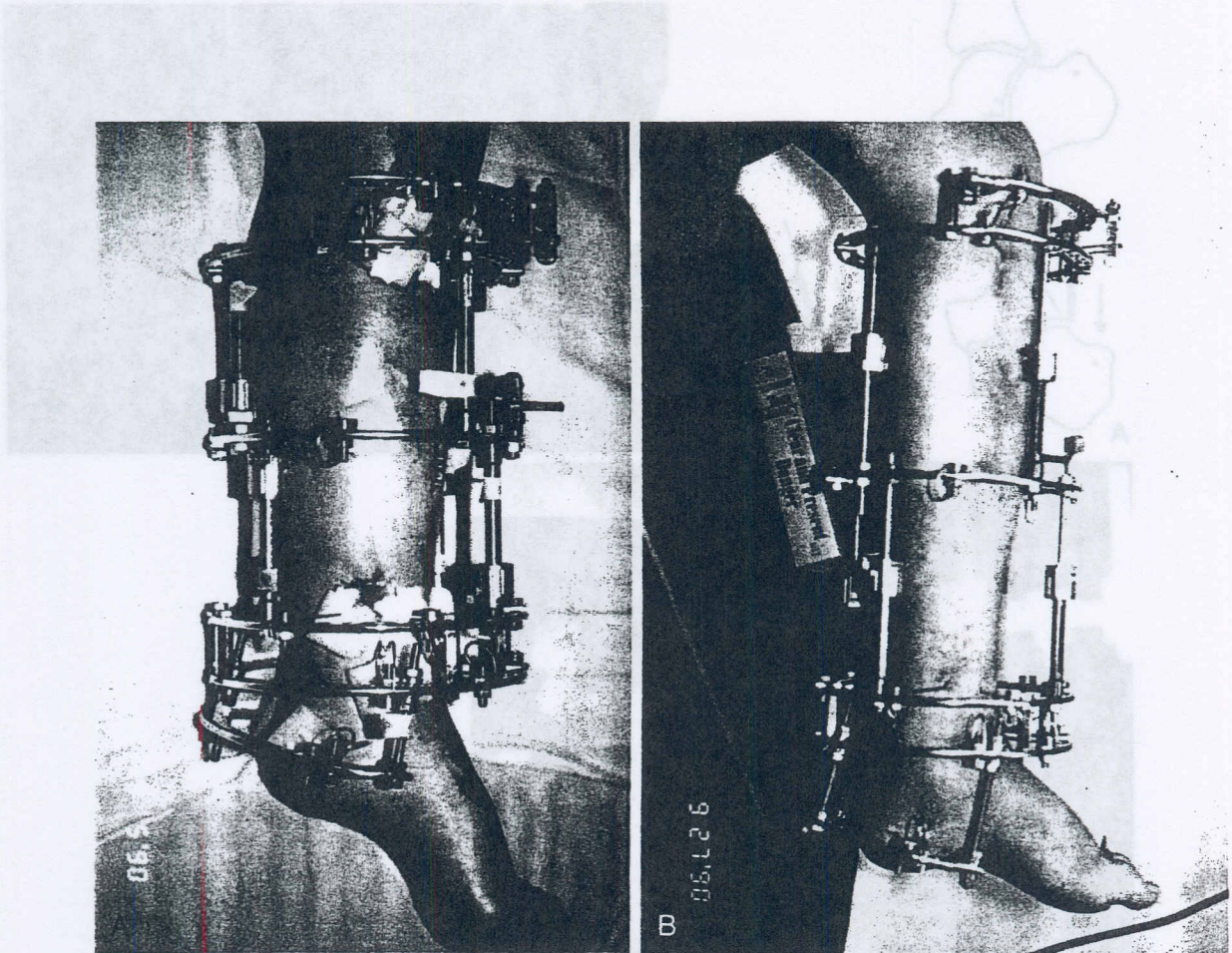


FIGURE 31-4. (A), A patient at the beginning of unconstrained equinus deformity correction combined with a two-level tibial lengthening. Note that the posterior heel rods are not parallel to the tibia. (B), Toward the end of correction, note the position of the heel ring. It is posteriorly displaced relative to the distal tibial ring. This keeps the talus in the mortise. (Courtesy of Dror Paley, M.D.)

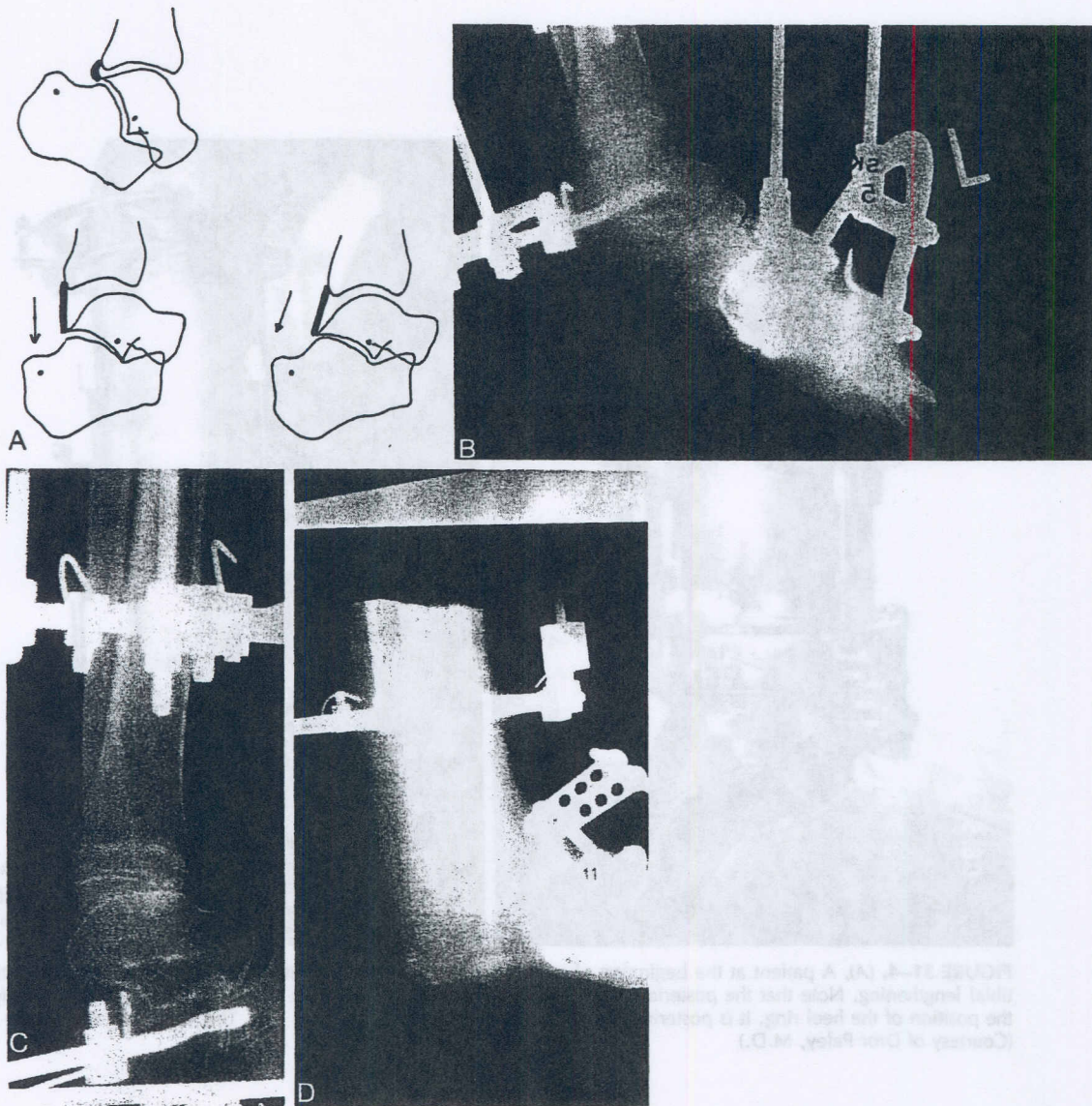


FIGURE 31-5. If distraction is performed in a purely axial direction, perpendicular to the distal tibial ring and parallel to the tibia, the ankle will tend to sublux forward (*A, left*). If distraction is performed in a posteriorly inclined direction, the ankle does not sublux (*A, right*). A clinical example of this phenomenon is shown at the beginning of distraction (*B*), when the posterior heel rods are parallel to the tibia, during distraction (*C*), demonstrating anterior subluxation, and after correction of subluxation (*D*). (Courtesy of Dror Paley, M.D.)

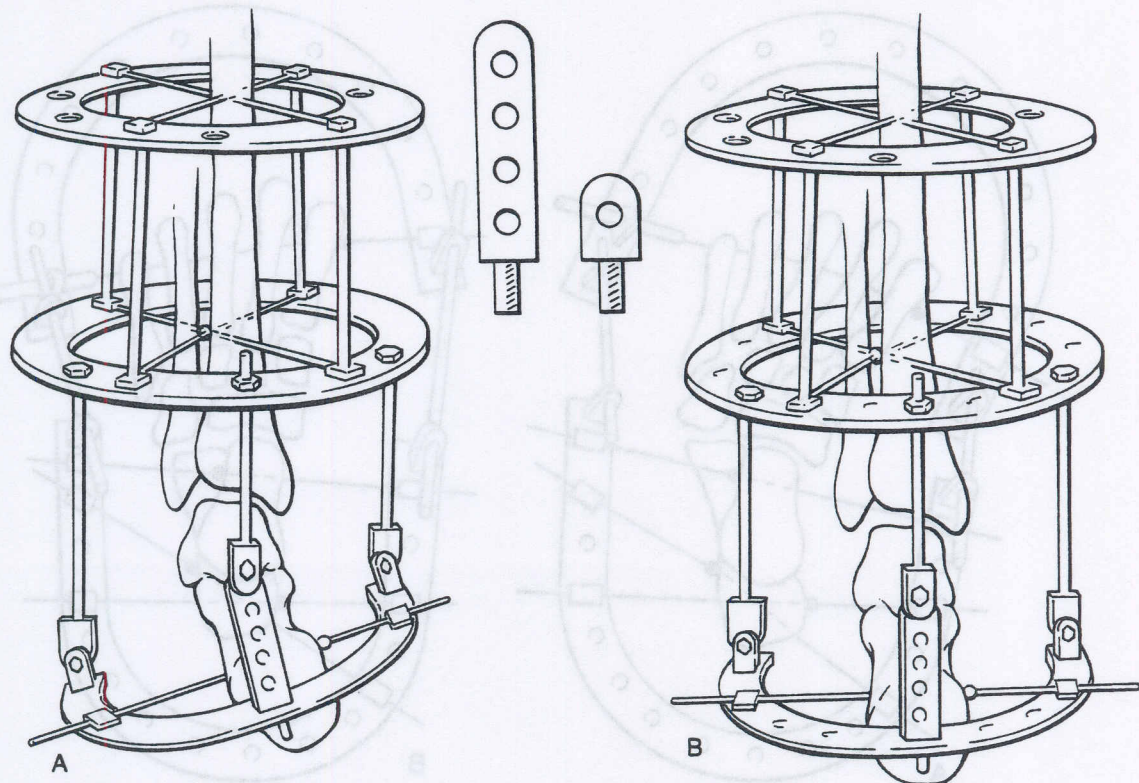


FIGURE 31-6. (A), The drawing of the construct for correction of varus deformity is shown from the posterior view. This construct uses the standard two-ring fixation on the tibia, with two wires at each level and one with an olive placed laterally. One wire uses one hinge medially and one laterally on the half-ring. The main hinge is posterior and uses a three- or four-hole post (*inset*) to raise it above the level of the other two so that it is closer to the center of rotation of the subtalar joint. The level of this hinge also serves to force the olive on this half-ring against the body of the calcaneus to correct the varus deformity. (B), At the end of correction, the rings are parallel and the contracture of the subtalar joint is reduced.

the heel wire. In this way, as the medial side is distracted, because it has to pivot around the hinge, it will translate laterally, forcing the heel out of varus. The rods medially and laterally are connected with a hinge distally and conical washers proximally, or with twisted plates that have pivot points at both ends, or with a mixture of the two. The choice depends on the degree of deformity. Conical washers can adapt only to a 7.5-degree tilt in either direction. The correction is produced by asymmetrical distraction of all three rods. The medial rod is lengthened at five 0.25-mm adjustments per day, the middle rod at three 0.25-mm adjustments per day, and the lateral rod at one 0.25-mm adjustment per day. In this manner, there is no risk of crushing of the joint surfaces.

Equinovarus Deformity

Correction of equinovarus deformity is essentially performed with a combination of the two previous constructs. The olive wires in the tibial construct must resist the equinus distraction as well as the varus distraction. Therefore, an anterolateral olive wire is used distally as a medial-face wire, and a posteromedial olive wire is used proximally as a medial-face wire.¹¹ If a hybrid construct using half-pins and wires is used, olive wires are not necessary. Smooth wires are used instead. An olive wire is used in the heel to pull the foot out of varus. The heel ring is tilted 7 degrees for the equinus to resist the anterior translation and is tilted the number of degrees of varus, as needed. The varus tilt is on the distal half-ring, whereas the

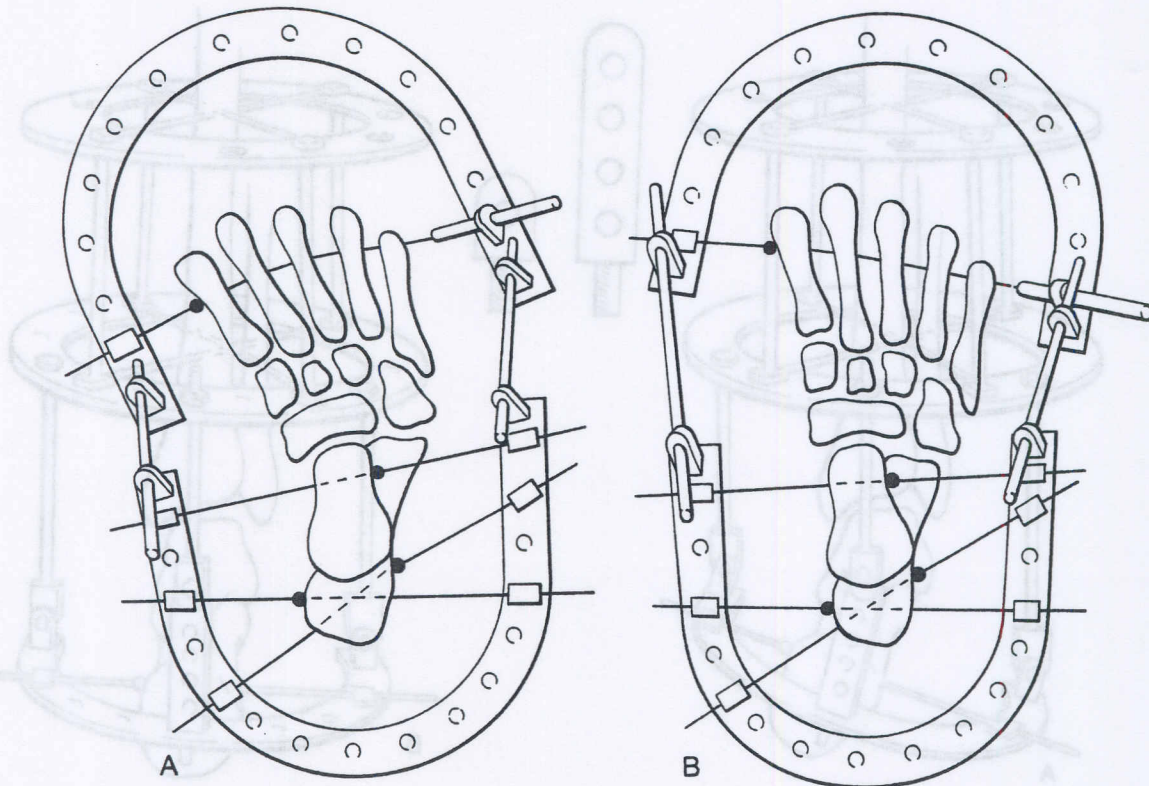


FIGURE 31-7. (A), Adductus deformity correction is performed using a half-ring for the forefoot and one for the hindfoot, which are articulated by threaded rods suspended off posts. Two olive wires are fixed into the calcaneus with olives on either side; one olive wire is fixed into the talus with an olive on the lateral side; and one olive wire is fixed into the metatarsals with an olive on the medial side. This forms a three-point bending mechanism in which the midfoot and forefoot are distracted away from the fixed hindfoot. The distraction is produced by the threaded rods connecting the two half-rings and by a translation mechanism in the form of a slotted threaded rod that is connected to the distal wire. Note that the medial edge of the distal wire is fixed using a buckle onto the half-ring so as to allow it to slide as the translation of the metatarsals is carried out. (B), At the end of the correction, the metatarsals are realigned and even overcorrected into abductus. The fifth metatarsal lies closer to the ring. The distal wire passes through only the first and fifth metatarsals and goes under the second, third, and fourth metatarsals.

equinus tilt is on the conical washers on the tibial ring. The distraction rate chosen is five 0.25-mm adjustments per day on the medial rod, four 0.25-mm adjustments per day on the posterior rod, and three 0.25-mm adjustments per day on the lateral rod.

Alternatively, a constrained construct can be used for equinovarus. This would involve application of a foot construct with hinges medially and laterally for the equinus, as described earlier, centered on the center of rotation of the ankle joint. The varus complicates the application of the hinges. The physician can accommodate for the varus by conical washers proximally if the amount of varus is not very large. For a larger amount of varus,

a biplanar hinge is used. This is made up of two half-hinges, which are at a 90-degree angle to each other. Alternatively, if universal hinges are available, they are much easier to use. They will accommodate for both the varus and the equinus. They need to be oriented for the varus. A distraction rod is placed posteriorly, with a biplanar hinge distally and a uniplanar pivot proximally.

Adductus Deformity (Figs. 31-7 and 31-8)

Adductus deformity can be corrected by a simple oval frame from the hindfoot to the

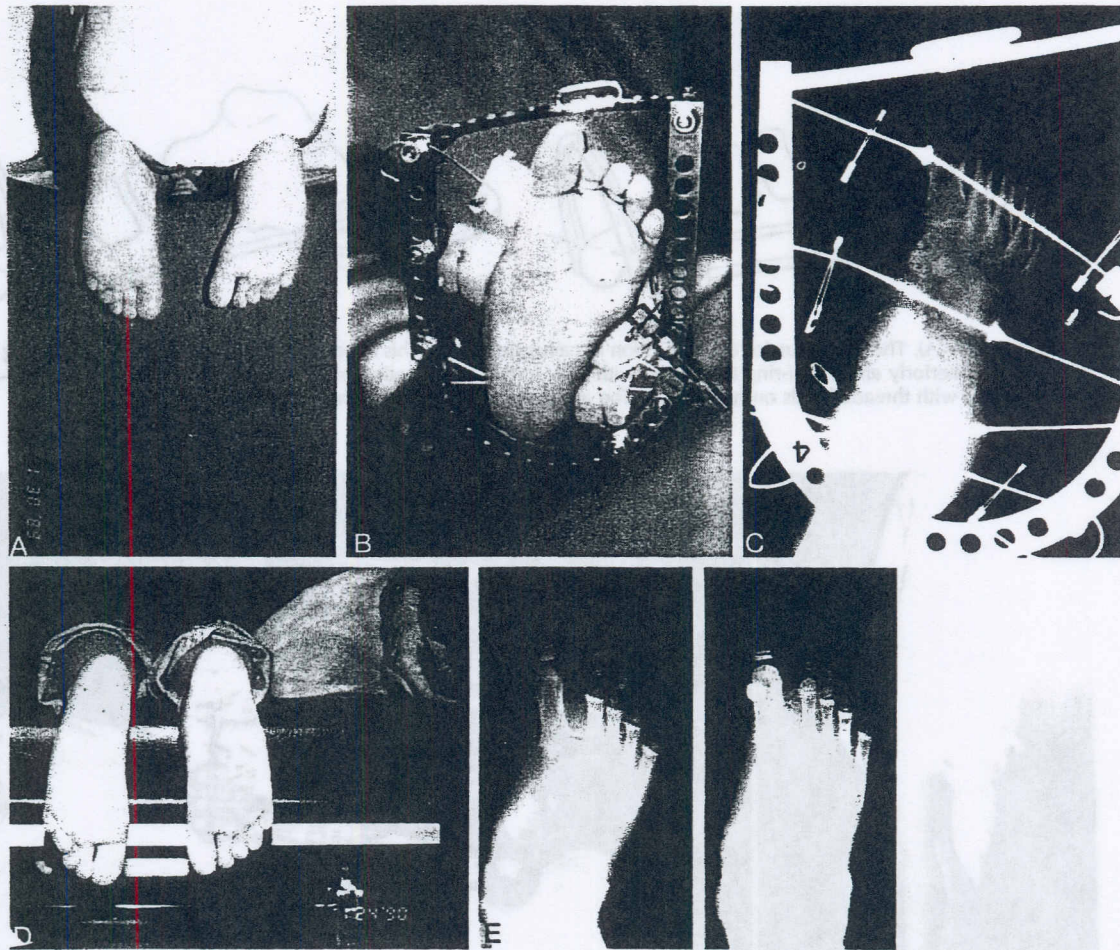


FIGURE 31-8. (A), A 4-year-old boy with a persistent metatarsus adductus and a skewfoot despite previous casting. (B), The foot is shown in the apparatus during treatment. (C), The radiograph at the end of treatment showing overcorrection. (D), The clinical appearance of the foot at 1-year follow-up. (E), The standing radiograph of the foot at the end of treatment (right) compared with before. (Courtesy of Dror Paley, M.D.)

forefoot. The oval is made up of two half-rings connected by plates. The correction is a three-point bending one, locking the calcaneus with two olive wires. One lateral olive wire goes across the neck of the talus or the navicular and cuboid, and one comes from the medial aspect of the first metatarsal into the fifth metatarsal. This metatarsal wire goes under the second, third, and fourth metatarsals. A slotted, threaded rod is connected to the distal wire, which slowly transports the forefoot laterally. Together with this, the medial column can be distracted from the lateral column. Instead of two plates being used to connect the two half-rings to form an oval, threaded rods are used.

Cavus Deformity (Figs. 31-9 to 31-11)

There are numerous types of constructs for cavus deformity correction. The simplest consists of a half-ring anteriorly and one posteriorly, with distraction between them. Fixation is by one wire in the heel and one in the forefoot. For overcorrection of cavus, one wire is placed at the apex of the deformity, which is either the neck of the talus or the navicular-cuboid row. If there is a base of fixation on the tibia, it can be used to pull up the forefoot relative to the hindfoot. Because cavus is frequently associated with equinus, the surgeon should first correct the equinus deformity and then correct the forefoot cavus deformity or

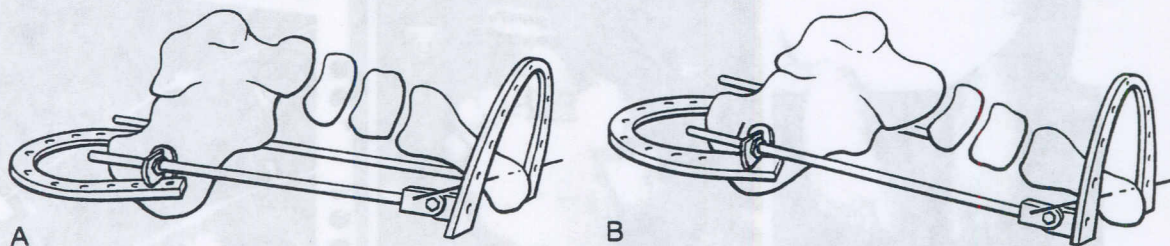


FIGURE 31-9. (A), The apparatus for the correction of cavus deformity. This apparatus may be very simple, including only a half-ring posteriorly and a half-ring anteriorly, with one- to two-wire fixation of the forefoot and hindfoot. The half-rings are distracted with threaded rods on hinges. (B), The appearance at the end of the distraction.

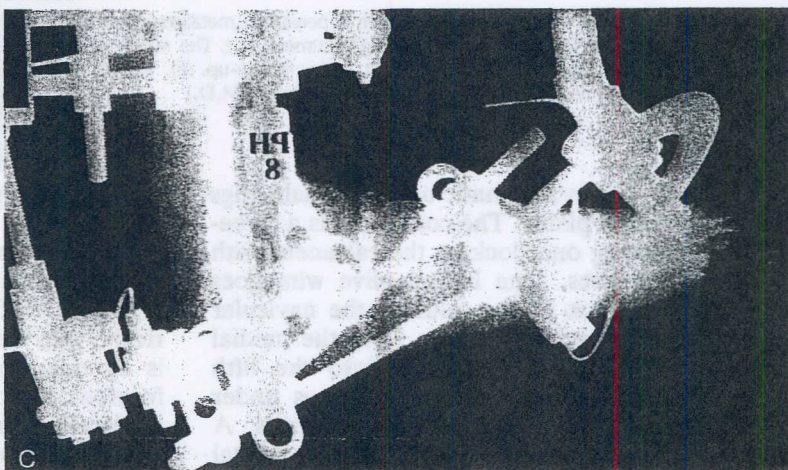

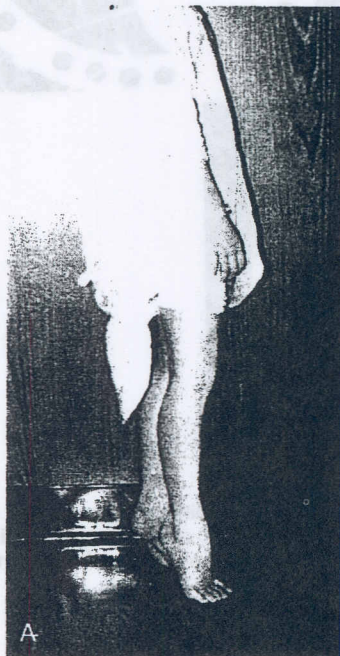


FIGURE 31-10. (A), A boy with a bilateral equinovarus foot deformity of congenital origin. (B), The apparatus was applied for the correction of the hindfoot equinus, followed by correction of the forefoot cavus. (C), The lateral radiograph during treatment. (A to C courtesy of Dror Paley, M.D.)

Illustration continued on following page

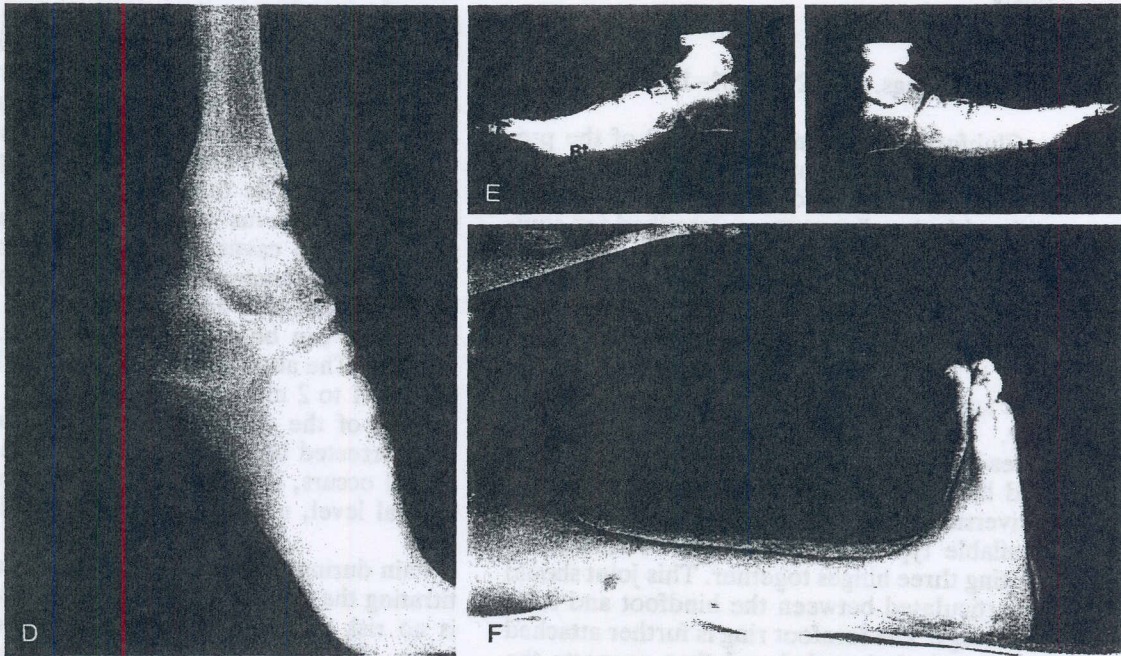


FIGURE 31-10 Continued (D), A lateral standing radiograph of the foot before the correction. (E), Radiographs of both feet at the end of the correction. Note the overcorrection achieved in the flattening of the arch on one of the sides, with plantar subluxation of the talonavicular joint on the left (Lt). One wire was placed in each navicular to act as a fulcrum for the correction. (F), The final clinical appearance shows no equinus or cavus deformity.

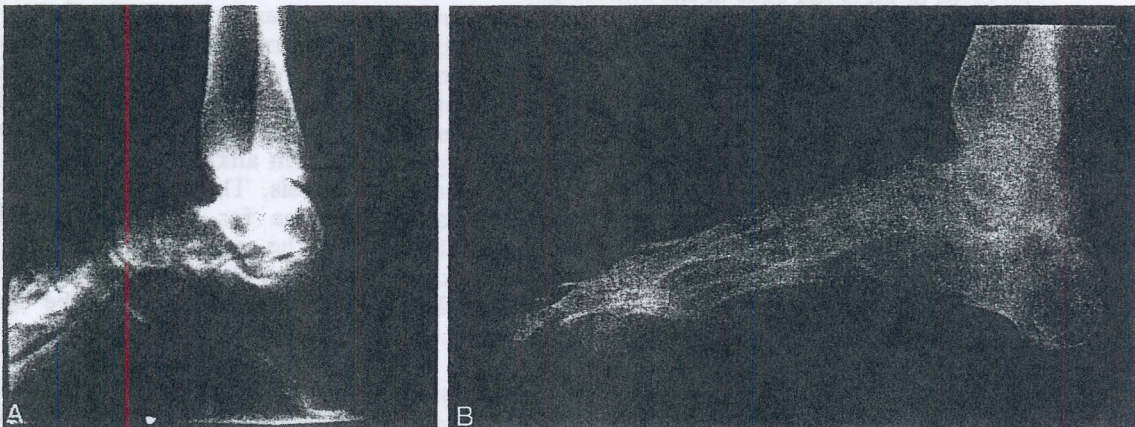


FIGURE 31-11. Combined forefoot and hindfoot cavus due to poliomyelitis. (A), The preoperative radiograph. Correction was performed using a posterior calcaneal osteotomy to decrease the calcaneal pitch and simultaneous distraction of the forefoot from the hindfoot, as well as elevation of the forefoot upward by pulling from the tibial ring. It should be noted that the rate of distraction of the forefoot upward should be approximately two times the rate of distraction of the forefoot away from the hindfoot. This is based on a mathematical calculation. (B), The final radiograph demonstrating the correction of the hindfoot and the forefoot equinus. (Courtesy of Dror Paley, M.D.)

should perform both corrections simultaneously.

Clubfoot (Figs. 31-12 and 31-13)

Clubfoot correction involves all of the previously mentioned constructs combined. In this correction, the use of a strong base on the tibia with the olive pattern described for equinovarus deformity is the first step. The heel ring is placed as it is for an equinovarus deformity. The distraction pattern for the hindfoot is as that described for equinovarus. The forefoot is fixed using a single wire through the first and fifth metatarsals with the olive medially. This is connected to a half-ring. A threaded rod medially connects the forefoot and hindfoot rings. It is preferable to have a universal joint, either of the commercially available type or one that can be created by putting three hinges together. This joint should be articulated between the hindfoot and forefoot rings. The forefoot ring is further attached to a vertical threaded rod that connects the tibial frame via a pivot point and twisted plate. This rod controls elevation of the forefoot, as well as supination and pronation. To this rod, I connect a push rod off a post. The push rod goes right to the vertical forefoot rod. Its function is to push the vertical rod laterally, thus helping to correct the adductus deformity. The pivot point is the base of the twisted plate on the tibial ring.

The order of correction is very important. Correction starts with distraction posteriorly in an asymmetrical fashion at a rate of 1 mm/day, as described for the equinovarus deformity. Simultaneously, the forefoot is pulled up at 1 mm/day. Because the forefoot ring is further from the center of ankle rotation than is the hindfoot ring, an opening wedge of the ankle joint will occur, thus stretching the posterior capsule more. This is the desired outcome. If pulling up is performed too quickly anteriorly, crushing of the anterior joint cartilage may occur. Therefore, radiographic monitoring of the lateral ankle is needed.

The medial and lateral rods, which are for the correction of the adductus deformity and the cavus deformity, are lengthened at 1 mm/day on the medial side and at 0.5 mm/day on the lateral side. If there is no cavus deformity, lengthening is at 1 mm/day on the medial side and at 0.25 mm/day on the lateral side. A

purely cavus correction would require approximately half the rate of distraction of the plantar aspect of the foot, as in pulling up on the foot. Once the equinus varus and adductus deformities have been corrected, the frame is converted for the correction of supination. Supination and pronation are corrected with two anterior rods. The surgeon pulls up more on the lateral side than on the medial side if simultaneous cavus correction is being performed. If no cavus correction is being performed, the surgeon can actually push down on the medial side and pull up on the lateral side. This can be done at a rate of 0.5 to 1 mm/day. The adductus push rod is also lengthened at 1 to 2 mm/day.

Each of the deformities treated should be overcorrected beyond the neutral level. If rebound occurs, it will only bring the foot to a neutral level, not into a nonplantigrade position.

Pain during distraction should be treated by titrating the dose of distraction. Because there is no risk of bony consolidation, there is no hurry. The surgeon can slowly distract to a level that the patient can tolerate.

Obviously, the younger the patient, the greater the expected growth and therefore the more potential for recurrence of the deformity. The less fixed bony deformity present, the smaller the chance for recurrence. The factors that the surgeon can alter that will decrease the risk of recurrence include the degree of overcorrection and the length of time in the fixator. Overcorrection of 20 to 30 percent can minimize the recurrence due to the rebound effect of the stretched soft tissues. After removal of the apparatus, the foot should be splinted with an ankle-foot orthosis or a total contact orthosis. The splint should be maintained full-time for at least 6 months and should then be used only at night for an extended period. Once the patient has reached skeletal maturity, splinting can be discontinued.

The length of time the apparatus is left in place after deformity correction is also important. In children, the apparatus should be removed approximately 6 weeks after the deformity has been fully distracted and corrected. In adults, a wait of 3 to 6 months after deformity correction is achieved may be necessary to prevent recurrence.

Recurrence can also be prevented by tendon transfer or selective arthrodeses after the dis-

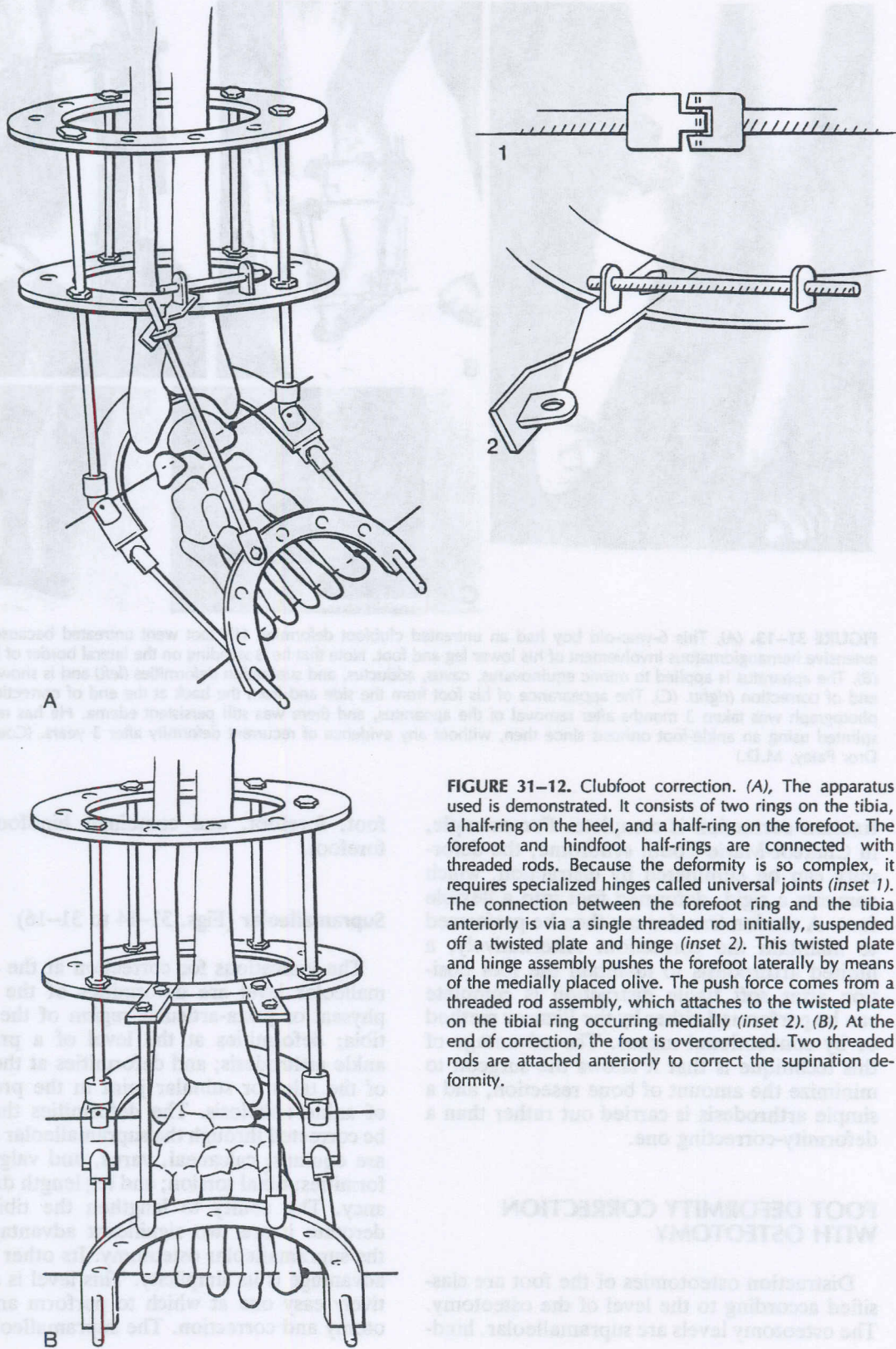


FIGURE 31-12. Clubfoot correction. (A), The apparatus used is demonstrated. It consists of two rings on the tibia, a half-ring on the heel, and a half-ring on the forefoot. The forefoot and hindfoot half-rings are connected with threaded rods. Because the deformity is so complex, it requires specialized hinges called universal joints (*inset 1*). The connection between the forefoot ring and the tibia anteriorly is via a single threaded rod initially, suspended off a twisted plate and hinge (*inset 2*). This twisted plate and hinge assembly pushes the forefoot laterally by means of the medially placed olive. The push force comes from a threaded rod assembly, which attaches to the twisted plate on the tibial ring occurring medially (*inset 2*). (B), At the end of correction, the foot is overcorrected. Two threaded rods are attached anteriorly to correct the supination deformity.

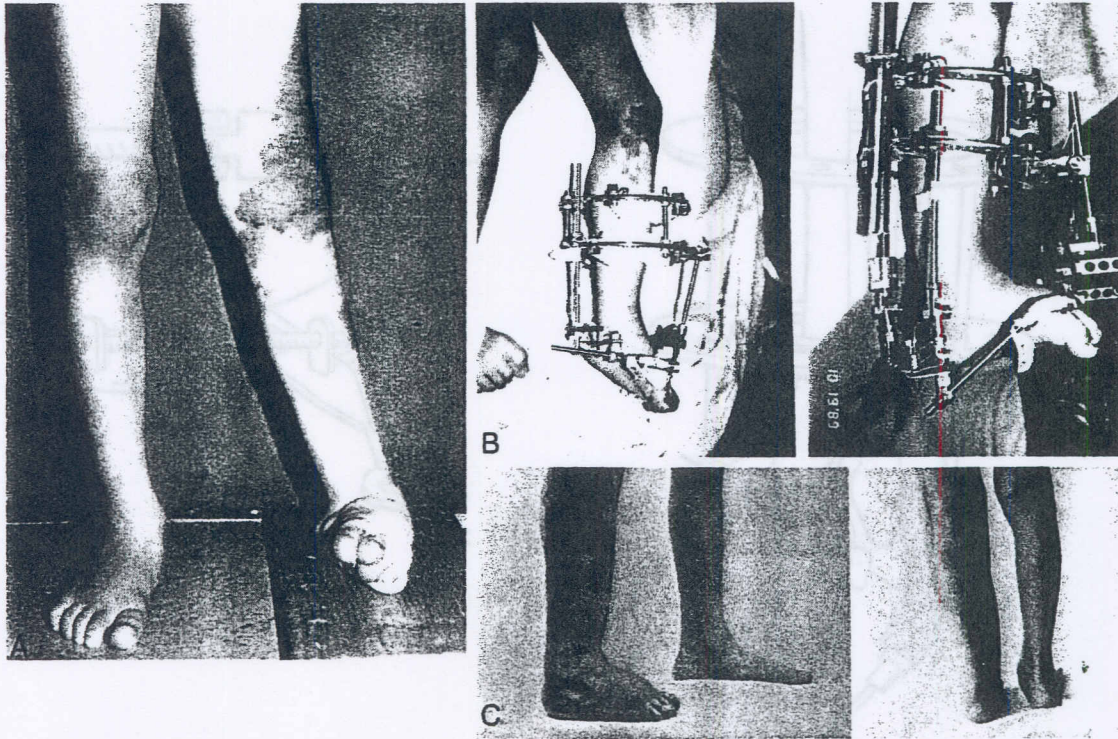


FIGURE 31-13. (A), This 6-year-old boy had an untreated clubfoot deformity. His foot went untreated because of the extensive hemangiomatous involvement of his lower leg and foot. Note that he is standing on the lateral border of his foot. (B), The apparatus is applied to mimic equinovarus, cavus, adductus, and supination deformities (left) and is shown at the end of correction (right). (C), The appearance of his foot from the side and from the back at the end of correction. This photograph was taken 3 months after removal of the apparatus, and there was still persistent edema. He has remained splinted using an ankle-foot orthosis since then, without any evidence of recurrent deformity after 3 years. (Courtesy of Dror Paley, M.D.)

traction correction is complete. For example, in Charcot-Marie-Tooth syndrome, the deformity can be eliminated by distraction, which converts a rigid, deformed foot into a flexible foot. A tendon transfer can then be performed to maintain the correction. Alternatively, a limited arthrodesis to maintain the foot position after soft tissue distraction is complete can be performed either by the Ilizarov method or by conventional means. The advantage of this technique is that it allows the surgeon to minimize the amount of bone resection, and a simple arthrodesis is carried out rather than a deformity-correcting one.

FOOT DEFORMITY CORRECTION WITH OSTEOTOMY

Distraction osteotomies of the foot are classified according to the level of the osteotomy. The osteotomy levels are supramalleolar, hind-

foot, forefoot, and combined hindfoot and forefoot.

Supramalleolar (Figs. 31-14 to 31-16)

The indications for correction at the supramalleolar level are deformities of the metaphyseal or juxta-articular region of the distal tibia; deformities at the level of a previous ankle arthrodesis; and deformities at the level of the talus or subtalar joint in the presence of ankle ankylosis. The deformities that can be corrected through the supramalleolar region are equinus; calcaneal, varus, and valgus deformities; tibial torsion; and leg length discrepancy. The ability to lengthen the tibia and derotate it are two significant advantages of the supramalleolar osteotomy. Its other major advantage is its simplicity. This level is a relatively easy one at which to perform an osteotomy and correction. The supramalleolar os-

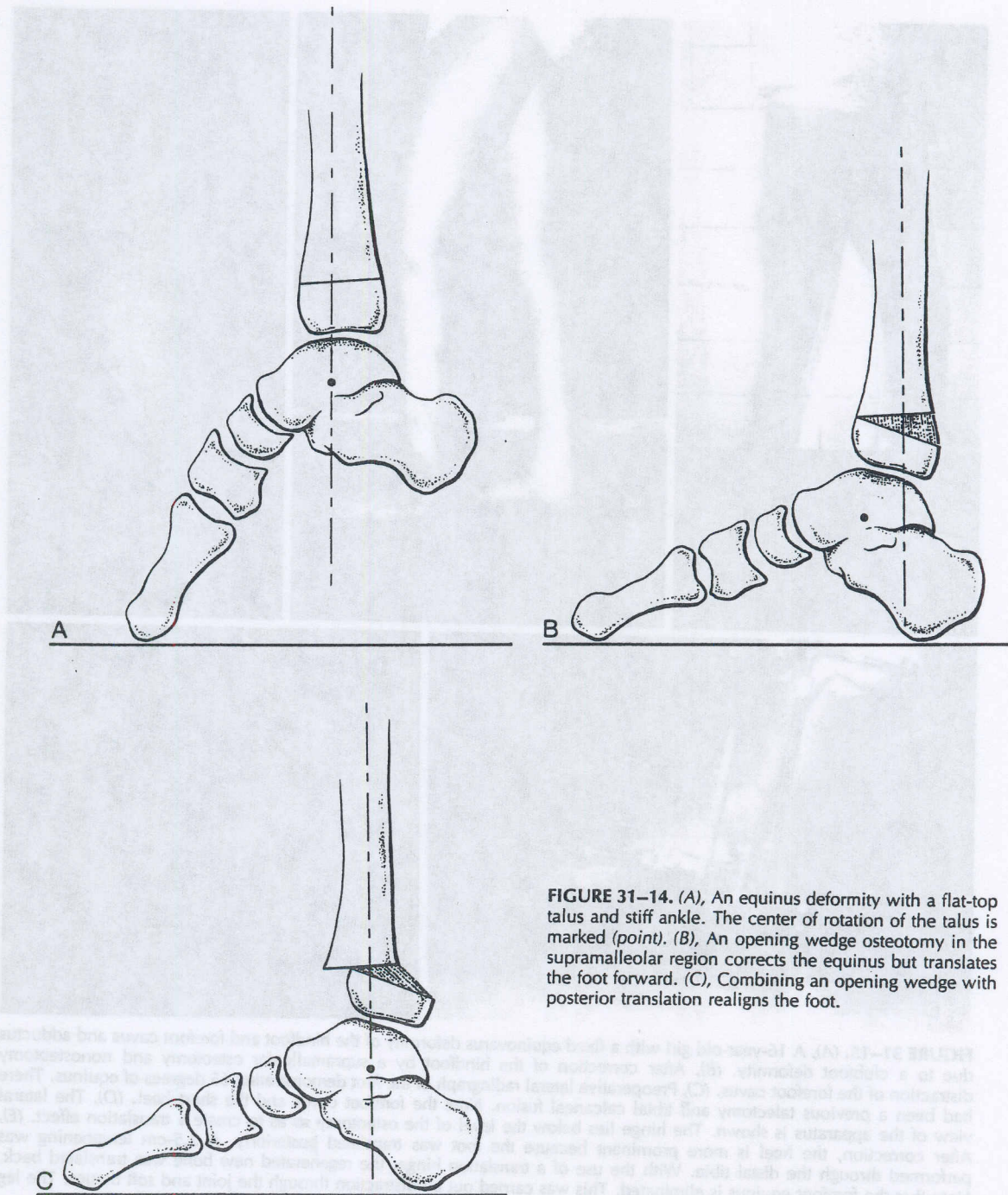


FIGURE 31-14. (A), An equinus deformity with a flat-top talus and stiff ankle. The center of rotation of the talus is marked (point). (B), An opening wedge osteotomy in the supramalleolar region corrects the equinus but translates the foot forward. (C), Combining an opening wedge with posterior translation realigns the foot.

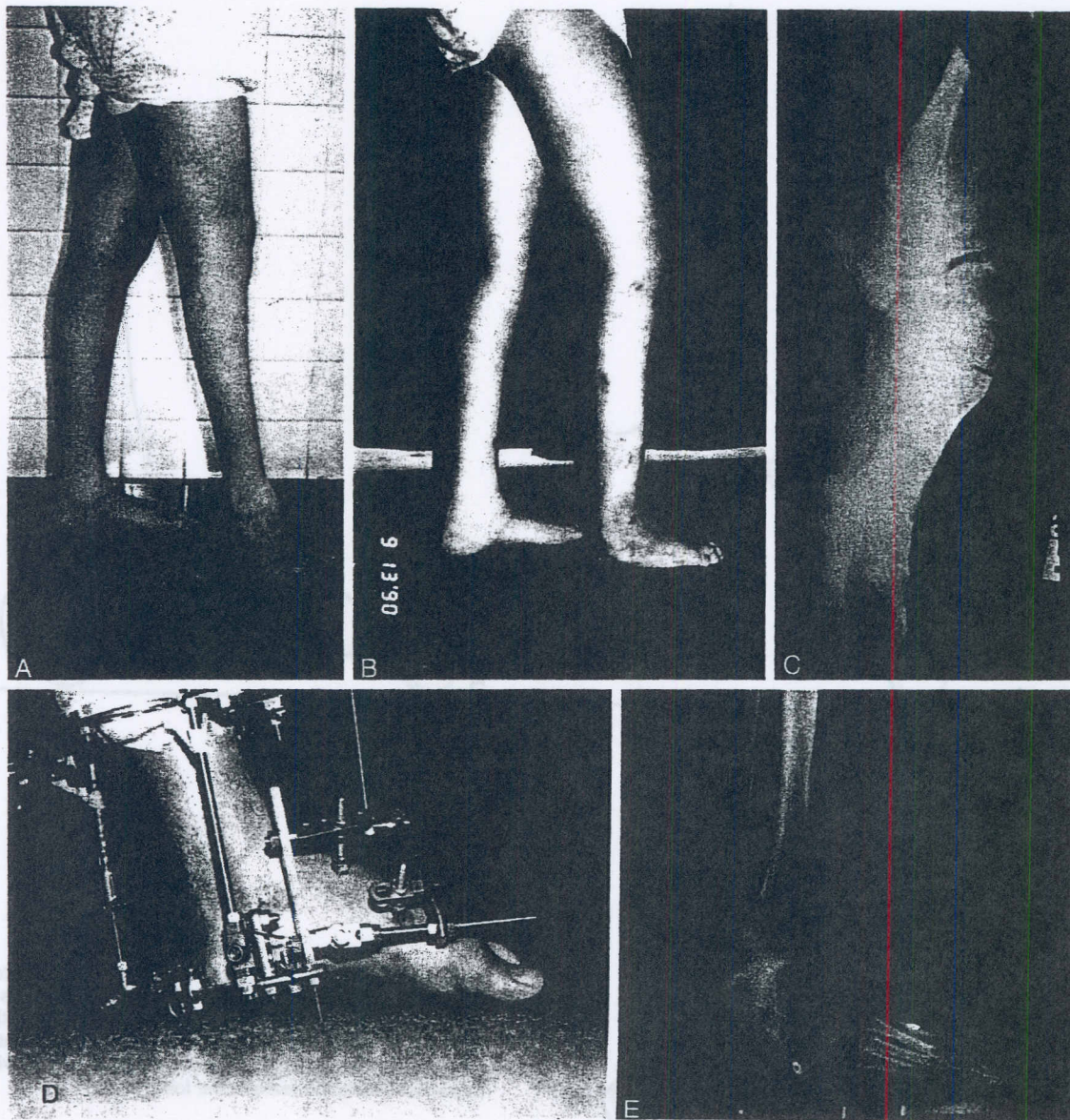

FIGURE 31-15. (A), A 16-year-old girl with a fixed equinovarus deformity of the hindfoot and forefoot cavus and adductus due to a clubfoot deformity. (B), After correction of the hindfoot by a supramalleolar osteotomy and nonosteotomy distraction of the forefoot cavus. (C), Preoperative lateral radiograph of the foot demonstrating 65 degrees of equinus. There had been a previous talectomy and tibial calcaneal fusion. Note the forefoot cavus and the short heel. (D), The lateral view of the apparatus is shown. The hinge lies below the level of the osteotomy so as to create a translation effect. (E), After correction, the heel is more prominent because the foot was translated posteriorly. A 2.5-cm lengthening was performed through the distal tibia. With the use of a translation hinge, the regenerated new bone was translated back. Note that the forefoot equinus is eliminated. This was carried out by distraction through the joint and soft tissues. The leg was also simultaneously widened for cosmesis. (Courtesy of Dror Paley, M.D.)

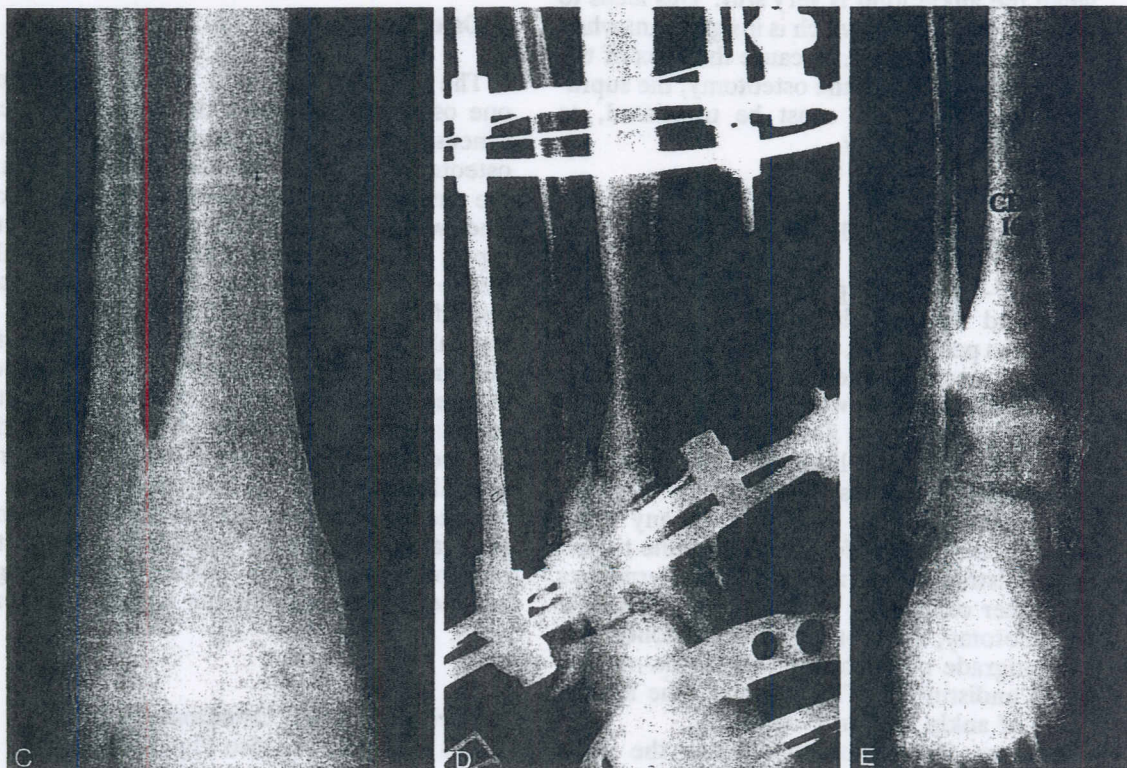
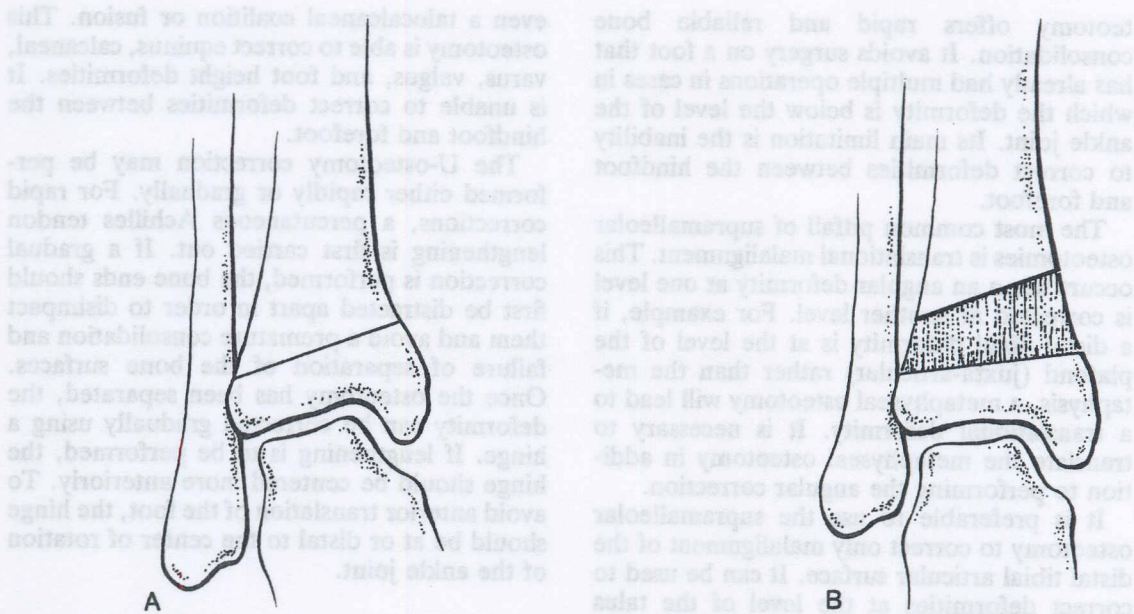


FIGURE 31-16. (A), Varus deformity of the distal tibia with shortening relative to the fibula. (B), Supramalleolar osteotomy with distraction and correction of the varus deformity and differential lengthening of the tibia relative to the fibula. (C), A post-traumatic varus deformity of the distal tibia with shortening of the tibia relative to the fibula, as in B. (D), A supramalleolar osteotomy was performed. (E), The final radiographic appearance after correction of the varus deformity and lengthening of the tibia relative to the fibula by 1.5 cm. (C to E courtesy of Dror Paley, M.D.)

The majority of patients with a pre-existing still subsist joint or may be present. It can also be used for bony
 This have a pre-existing still subsist joint or may be present. It can also be used for bony
 For continued on page 301

teotomy offers rapid and reliable bone consolidation. It avoids surgery on a foot that has already had multiple operations in cases in which the deformity is below the level of the ankle joint. Its main limitation is the inability to correct deformities between the hindfoot and forefoot.

The most common pitfall of supramalleolar osteotomies is translational malalignment. This occurs when an angular deformity at one level is corrected at another level. For example, if a distal tibial deformity is at the level of the plafond (juxta-articular) rather than the metaphysis, a metaphyseal osteotomy will lead to a translational deformity. It is necessary to translate the metaphyseal osteotomy in addition to performing the angular correction.

It is preferable to use the supramalleolar osteotomy to correct only malalignment of the distal tibial articular surface. It can be used to correct deformities at the level of the talus when the ankle joint is very stiff. This leads to a tilt of the plafond, which is insignificant when the ankle is very stiff. Because the apex of the deformity is distal to the osteotomy, the supramalleolar osteotomy must be translated, as mentioned previously.

U-Osteotomy (Figs. 31-17 to 31-19)

The U-osteotomy² passes under the subtalar joint and through the superior part of the calcaneus posteriorly, and across the sinus tarsi and the neck of the talus anteriorly. It is indicated in cases in which the deformity is in the talus, such as in a flat-top talus. In the flat-top talus, there is a limited range of painless ankle motion. Because the joint is not spherical, it would not be congruous in any other position and is therefore not amenable to soft tissue distraction or release. The alternatives are either osteotomy or arthrodesis. With the U-osteotomy, the foot can be repositioned into a plantigrade position while the ankle mortise is left undisturbed. This preserves the limited range of ankle motion available.

Because the osteotomy crosses the sinus tarsi, an absolute prerequisite is a stiff subtalar joint. If the U-osteotomy is performed in the presence of a normal subtalar joint, subtalar motion will be blocked and lost. Fortunately, the majority of patients who have a flat-top talus have a pre-existing stiff subtalar joint or

even a talocalcaneal coalition or fusion. This osteotomy is able to correct equinus, calcaneal, varus, valgus, and foot height deformities. It is unable to correct deformities between the hindfoot and forefoot.

The U-osteotomy correction may be performed either rapidly or gradually. For rapid corrections, a percutaneous Achilles tendon lengthening is first carried out. If a gradual correction is performed, the bone ends should first be distracted apart in order to disimpact them and avoid a premature consolidation and failure of separation of the bone surfaces. Once the osteotomy has been separated, the deformity can be corrected gradually using a hinge. If lengthening is to be performed, the hinge should be centered more anteriorly. To avoid anterior translation of the foot, the hinge should be at or distal to the center of rotation of the ankle joint.

V-Osteotomy (Figs. 31-20 to 31-23)

The V-osteotomy² is a double osteotomy: one osteotomy is across the body of the calcaneus posterior to the subtalar joint, and one osteotomy is across the neck of the talus and the anterior calcaneus, through the sinus tarsi. The two osteotomies converge on the plantar aspect of the calcaneus. This leaves a triangular wedge of calcaneus and subtalar joint connected by the posterior facet to the body of the talus. The V-osteotomy is indicated for deformities between the hindfoot and forefoot. A prerequisite for this osteotomy is a stiff subtalar joint. Essentially all foot deformities can be corrected through the V-osteotomy, including hindfoot and forefoot equinus or calcaneal deformities, rocker-bottom deformities, cavus deformities, abductus and adductus deformities, and even deformities of length and bony deficiency of the hindfoot or forefoot.

Posterior Calcaneal Osteotomy (Figs. 31-24 to 31-26; see also Fig. 31-11)

The posterior calcaneal osteotomy^{6,7} is the same as the posterior limb of the V-osteotomy and the Dwyer osteotomy. It is used in deformities of the hindfoot when no forefoot deformity is present. It can also be used for bony

Text continued on page 501

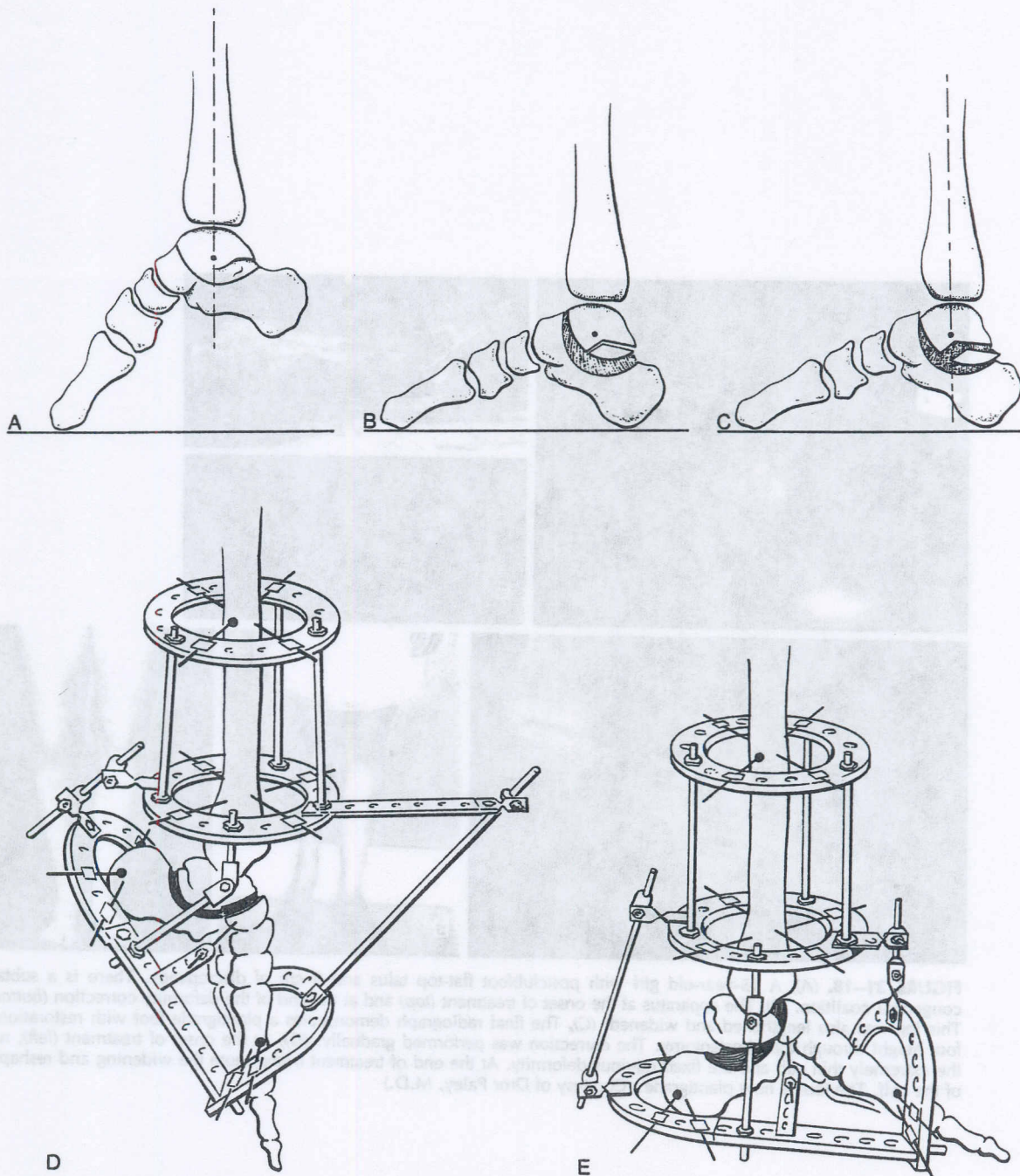


FIGURE 31-17. U-osteotomy. (A), Equinus deformity with flat-top talus. The U-osteotomy passes across the neck of the talus, through the sinus tarsi, and under the subtalar joint to exit posteriorly in the calcaneus. (B), Correction of the equinus is performed by slight distraction followed by rotation around the center of rotation of the ankle. (C), For acute corrections through the dome-shaped U-osteotomy, the head of the talus translates proximally in front of the ankle joint. (D), The apparatus at the onset of treatment. Note the location of the hinge. The head of the talus is fixed with a wire. There is a wire through the hinges to fix the body of the talus. (E), At the end of correction (acute), the head of the talus rides proximally.

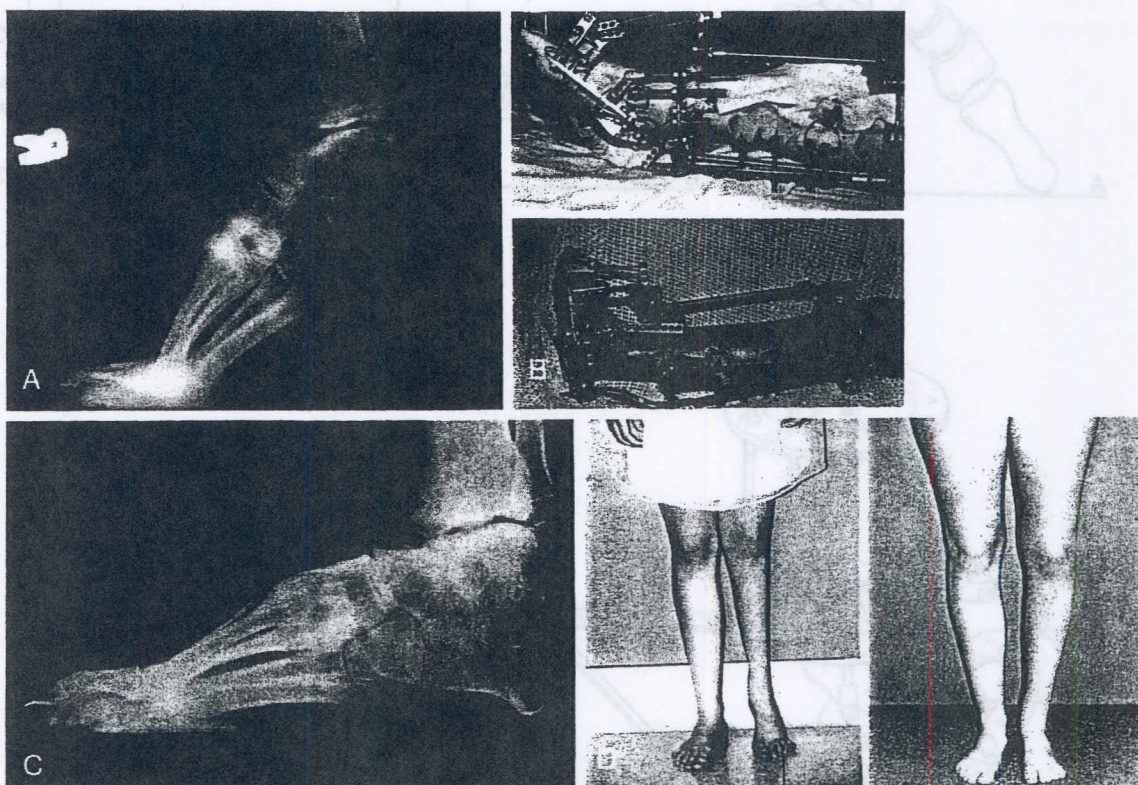


FIGURE 31-18. (A), A 15-year-old girl with postclubfoot flat-top talus and 8 cm of discrepancy. There is a subtalar congenital coalition. (B), The apparatus at the onset of treatment (top) and at the end of the deformity correction (bottom). This leg was also lengthened and widened. (C), The final radiograph demonstrates a plantigrade foot with restoration of foot height through the U-osteotomy. The correction was performed gradually. (D), At the onset of treatment (left), note the extremely thin calf and the fixed equinus deformity. At the end of treatment (right), note the widening and reshaping of the calf. The foot is now plantigrade. (Courtesy of Dror Paley, M.D.)

FIGURE 31-17. U-osteotomy. (A) Bone is debrided with sharp curet. The U-osteotomy begins across the neck of the talus, through the sinus tarsi, and under the subtalar joint to exit posteriorly in the calcaneus. (B) Correction of the equinus deformity by slight distraction followed by rotation around the center of rotation of the talus. (C) For some corrections a gradual but dome-shaped U-osteotomy, the head of the talus consists proximally in front of the ankle joint. (D) The apparatus at the onset of treatment. Note the location of the finger. The head of the talus is fixed with a wire. There is a wire through the finger to fix the body of the talus. (E) At the end of correction (acute), the head of the talus sits proximally.

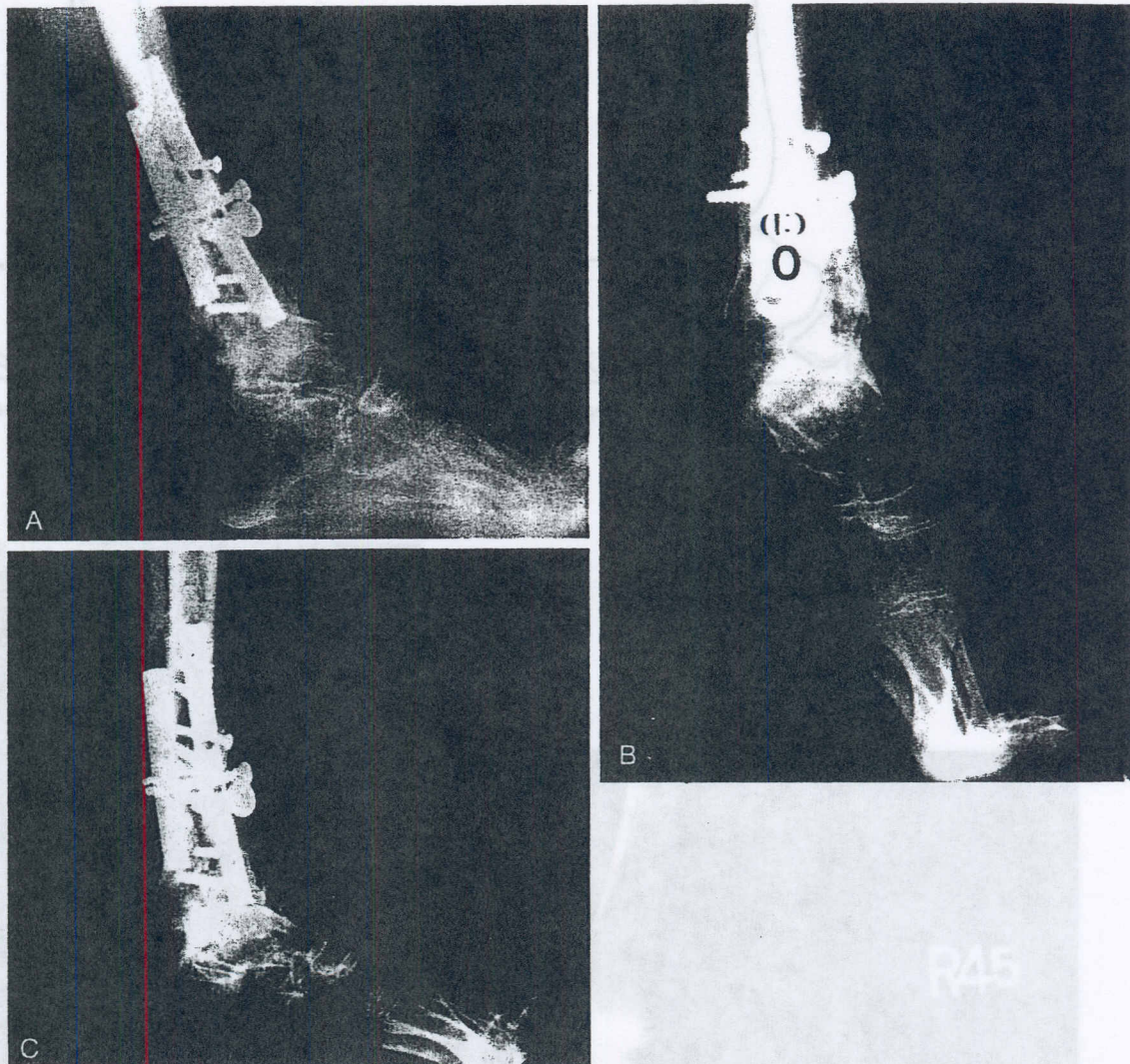


FIGURE 31-19. (A), Lateral standing radiograph of a fixed equinus deformity in a woman with juvenile rheumatoid arthritis and a triangular-top talus. (B), The U-osteotomy. (C), The lateral radiograph after correction, demonstrating the acute correction around a U-osteotomy. Note the step in the neck of the talus. (Courtesy of Dror Paley, M.D.)

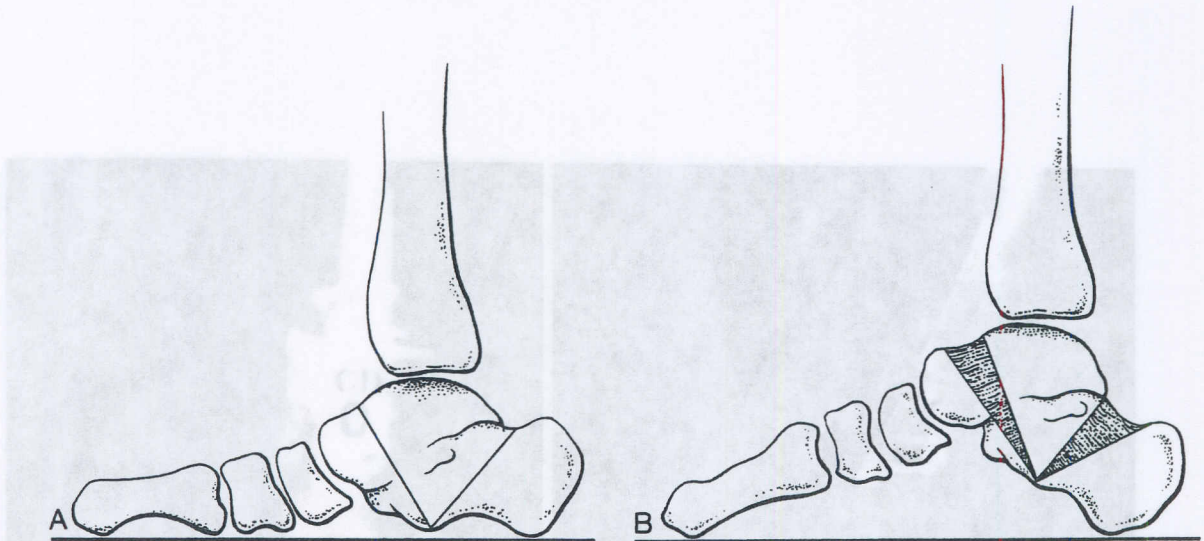


FIGURE 31-20. V-osteotomy. (A), V-osteotomy for rocker-bottom foot. (B), Opening wedge corrections of both the hindfoot and forefoot, recreating the longitudinal arch.

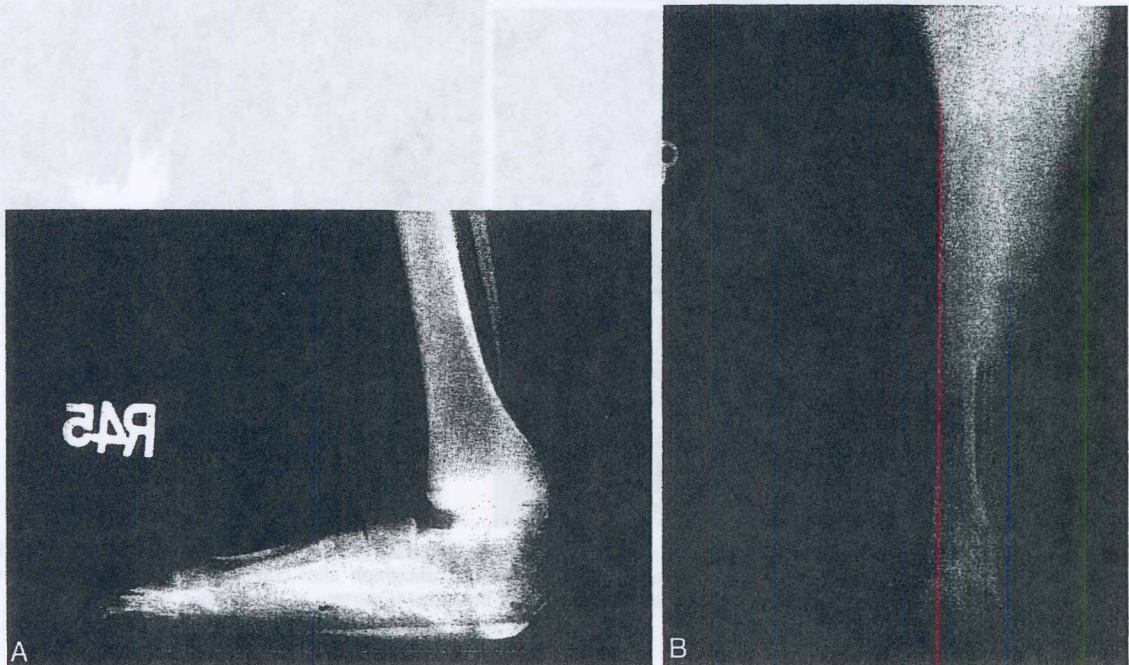


FIGURE 31-21. (A), A rocker-bottom foot deformity in an 11-year-old girl with an abnormally stiff ankle joint and a short hindfoot and forefoot. (B), Both the hindfoot and forefoot deformities were corrected by opening wedges using the V-osteotomy, recreating the longitudinal arch of the foot. (Courtesy of Dror Paley, M.D.)

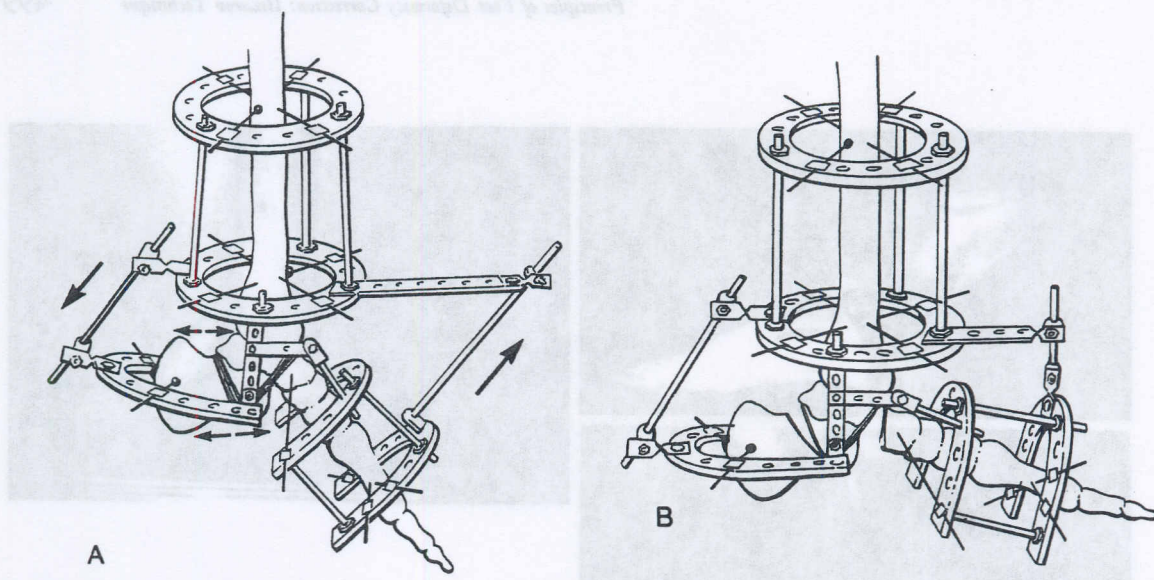


FIGURE 31-22. (A), The apparatus is used for a correction through a V-osteotomy. The deformity is similar to that in Figure 31-23. Note the position of the hinges at the apex of the deformities at the convex end of each osteotomy. (B), The apparatus after distraction of a V-osteotomy.

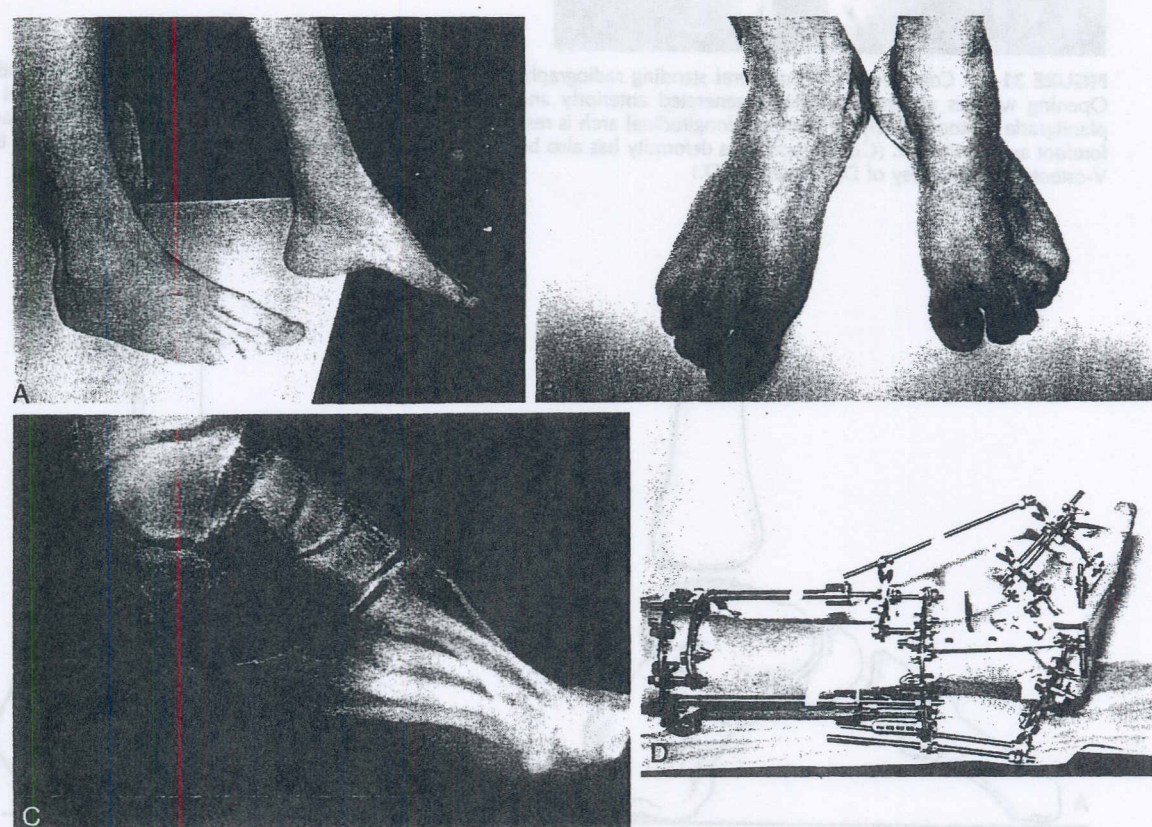


FIGURE 31-23. (A), A 16-year-old boy with residual clubfoot deformity; he has hindfoot equinus and forefoot cavus to different degrees. (B), His foot also has an adductus deformity. (C), The lateral radiograph demonstrates a flat-top talus. A V-osteotomy was performed to correct the hindfoot and forefoot deformities independently. The V-osteotomy can be seen on the radiograph before application of the apparatus. (D), The apparatus is quite complex. The anterior and posterior hinges are marked with asterisks. The tibia was simultaneously lengthened.

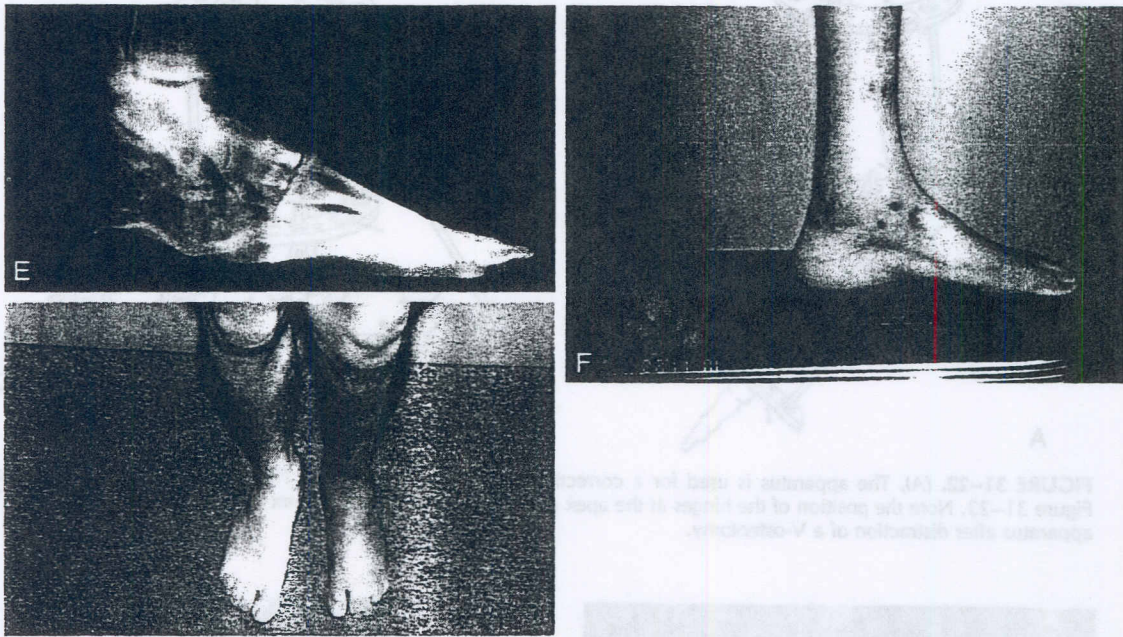


FIGURE 31-23 *Continued* (E), The lateral standing radiograph after distraction demonstrates that the foot is plantigrade. Opening wedges of new bone were generated anteriorly and posteriorly in the talus and calcaneus. (F), The foot is plantigrade postoperatively. The normal longitudinal arch is restored, and the equinus deformities of both the hindfoot and forefoot are eliminated. (G), The adductus deformity has also been corrected through the talocalcaneal neck portion of the V-osteotomy. (Courtesy of Dror Paley, M.D.)

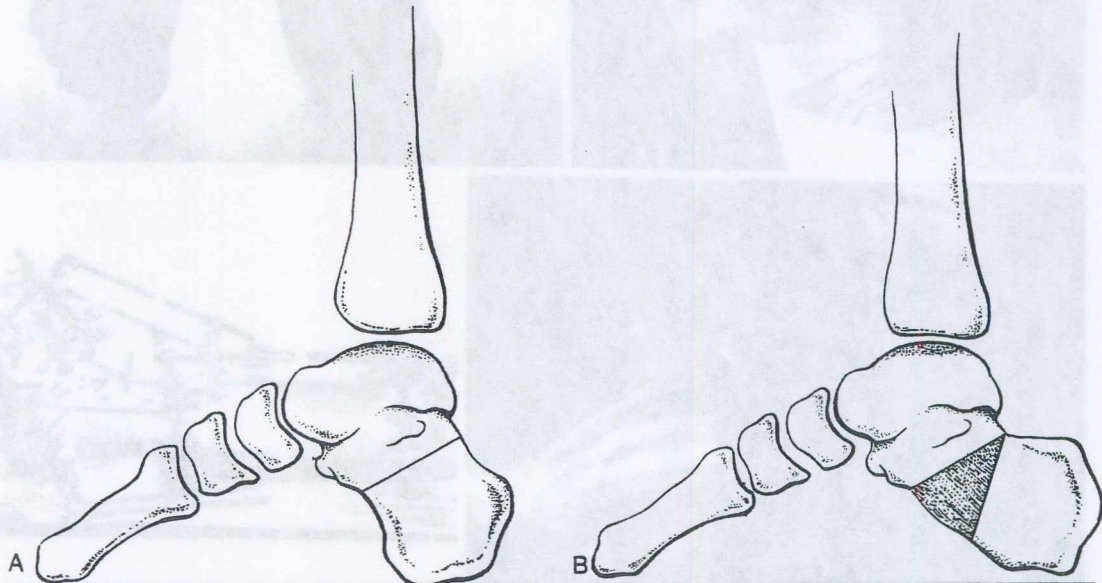


FIGURE 31-24. (A), The posterior calcaneal osteotomy is applied to a calcaneal cavus deformity. (B), A plantar opening wedge osteotomy is performed for the correction of this deformity. A clinical example is shown in Figure 31-11.

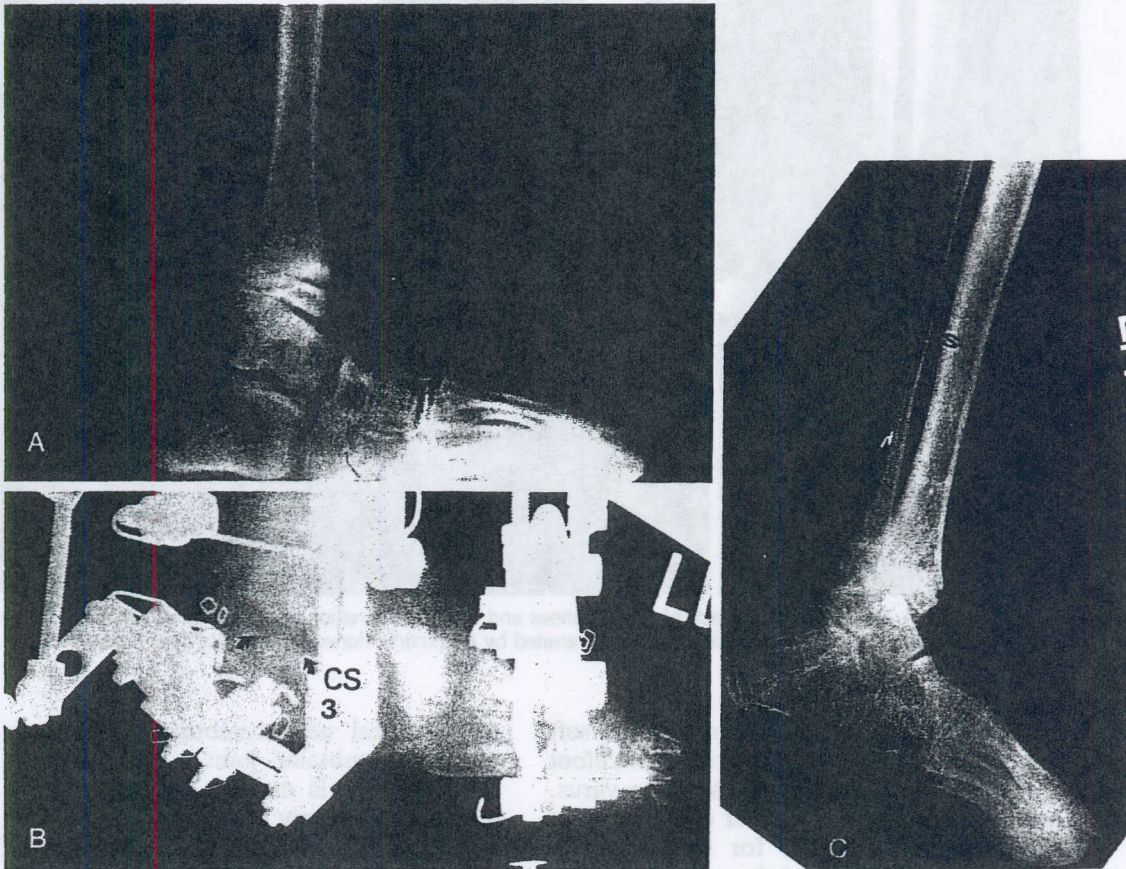


FIGURE 31-25. (A), Lateral radiograph of a 7-year-old girl with a varus rocker-bottom heel secondary to Streeter's syndrome. Her insensate foot was developing an area of breakdown under the prominent rocker-bottom apex. (B), A posterior calcaneal osteotomy was performed with simultaneous tibial lengthening and opening wedge correction of the calcaneal deformity. The calcaneal osteotomy prematurely consolidated due to lack of fixation of the anterior portion of the calcaneus. The path of least resistance was for distraction of the subtalar joint rather than the osteotomy. Note the diastasis of the subtalar joint (arrows). A repeated osteotomy was necessary to complete the treatment. (C), The final lateral radiograph demonstrates a plantigrade appearance to the plantar aspect of the foot. The heel ulcer promptly healed. (Courtesy of Dror Paley, M.D.)

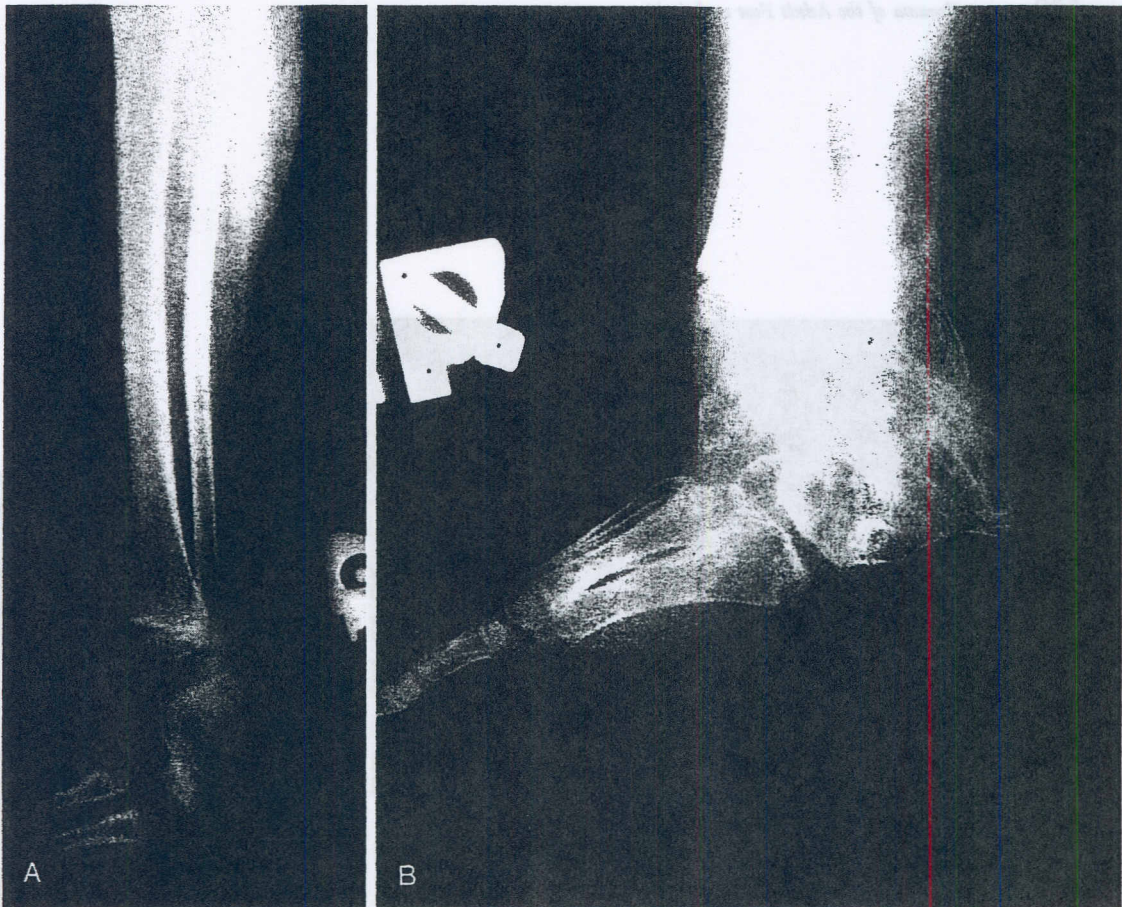

FIGURE 31-26. (A), Congenital deficiency of the calcaneus and supinated forefoot. (B), A posterior calcaneal osteotomy was used to regenerate a heel. The forefoot was demonstrated by distraction alone. (Courtesy of Dror Paley, M.D.)

correction of the hindfoot deformity while soft tissue correction is carried out on the forefoot deformity. Specifically, it is used for varus, valgus, equinus, and calcaneal deformities of the hindfoot, as well as for treating bone defects and deficiencies of the calcaneus.

Talocalcaneal Neck Osteotomies and Midfoot Osteotomies (Figs. 31-27 to 31-30)

The talocalcaneal neck osteotomy^{6, 7, 9, 16} is essentially the anterior limb of the V-osteotomy without the posterior calcaneal limb. This is used for the correction of forefoot deformities, including abductus, adductus, cavus, rocker-bottom, supination, and pronation deformities and shortening of the forefoot. The

talocalcaneal neck osteotomy is carried out when the subtalar joint is stiff. When the subtalar joint is mobile, I prefer to use the midfoot osteotomy across the cuboid and navicular or the cuboid and cuneiforms. The cuboid and navicular essentially form one fixed unit and have minimal to no mobility between them. This is therefore a safe plane with large, wide bony surfaces for bone regeneration.

Metatarsal Osteotomies (Fig. 31-31; see also Fig. 31-2)

Metatarsal osteotomies⁶ are most commonly used when individual metatarsals are shortened or deformed. Multiple-metatarsal osteotomies are generally not used for lengthening of the foot because of disturbance of the inter-

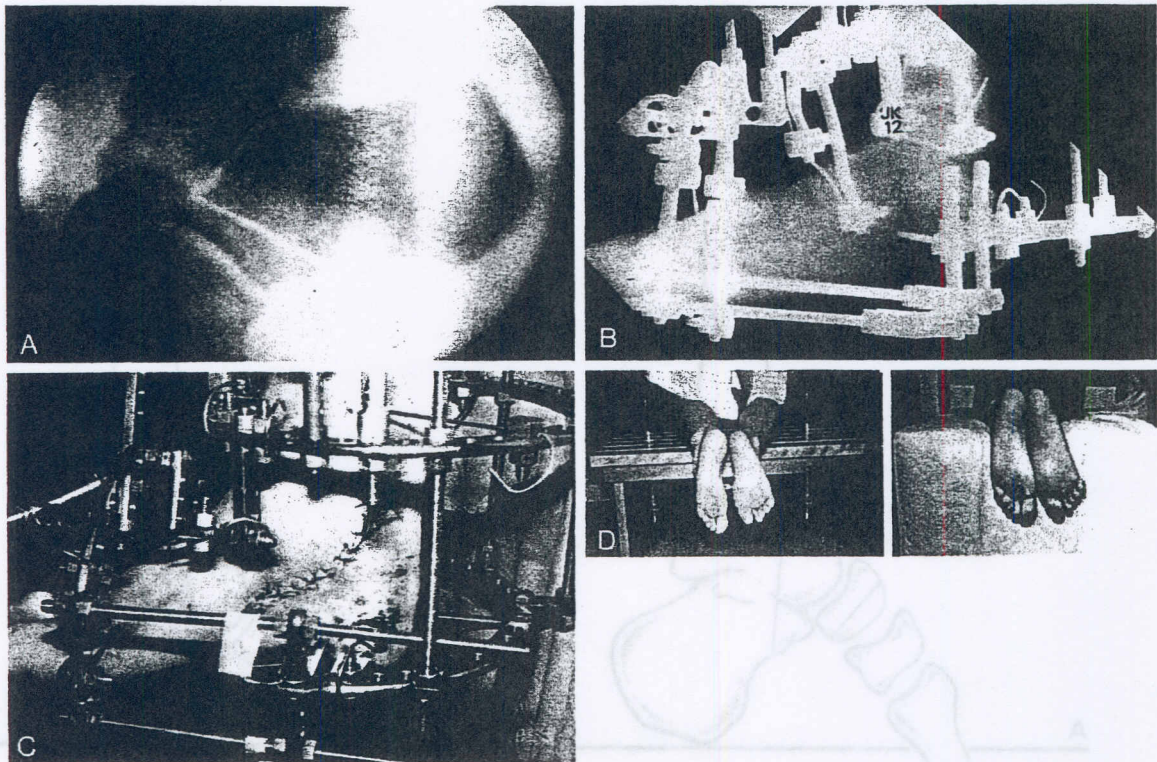


FIGURE 31-28. (A), Talocalcaneal neck osteotomy. (B), Lengthening of the foot through a talocalcaneal neck osteotomy. Note the regenerated bone between the anterior and posterior portions of the calcaneus. This boy had a ball-and-socket ankle joint and subtalar coalition in addition to a short foot. The foot was lengthened 3 cm. (C), He developed a postoperative tarsal tunnel syndrome, which was treated by an emergent release. (D), The appearance of the foot before (left) and after (right) lengthening. Note that the foot length discrepancy has been eliminated. (Courtesy of Dror Paley, M.D.)

ossei and the higher risk of injury to the neurovascular structures. Furthermore, stability and the healing rate are major factors with these bones and are less of a problem with the tarsal bones. Theoretically, there would be a significant risk of metatarsalgia if disruption of the arch were to occur. Therefore, the only indication for multiple-metatarsal lengthening or deformity correction is in cases in which there is a contraindication or significant absence or deficiency of the tarsal bones.

SURGICAL METHODS

Supramalleolar Osteotomy (see Fig. 31-12)

The preconstructed Ilizarov apparatus consists of proximal and distal blocks of two rings each: one at the proximal tibia and one just proximal to the planned supramalleolar oste-

otomy. The distal block consists of one supra-malleolar ring and sometimes of a calcaneal half-ring, in the case of a stiff or fused ankle joint. The two blocks are connected with a hinge. The hinge level is planned according to the level of the apex of the deformity. In true metaphyseal-level deformities, the hinge is proximal to the distal block, whereas in true juxta-articular deformities, the hinge lies at the level of the ankle joint below the ring and acts as a translation hinge. The osteotomy is performed either at the level of the apex of the deformity, if this is possible, or as distal as possible in the supramalleolar region, allowing adequate room for two levels of fixation. A distraction rod is connected to two twisted plates on the concave side. The twisted connections allow for a pivot point at either end of the distraction rod for self-adjustment of its alignment. Lengthening is accomplished by distracting the two hinge rods and the distraction rod.

Text continued on page 508

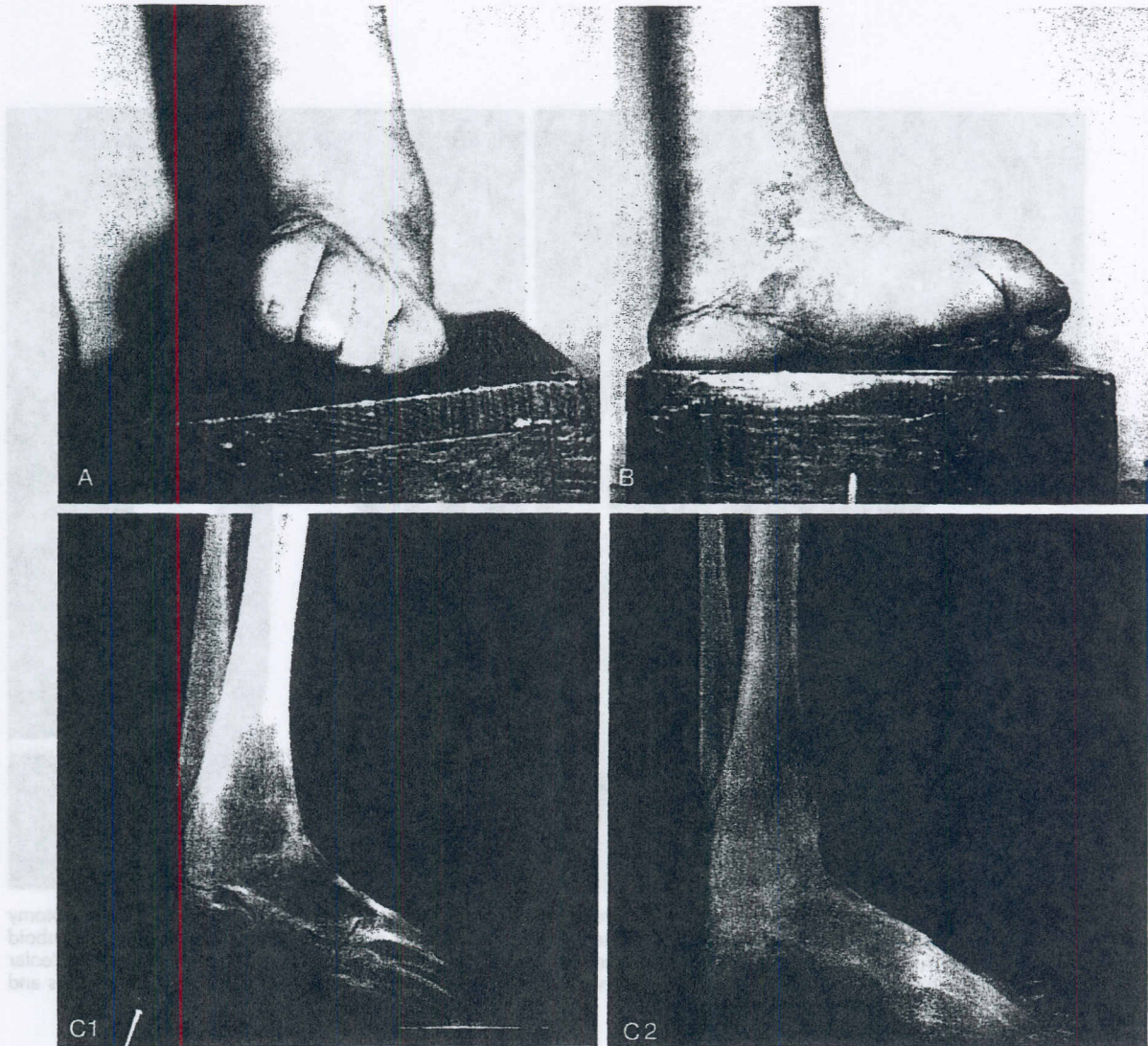


FIGURE 31-29. (A and B), Frontal and side views of the leg and foot of a 63-year-old man who suffered an injury at the age of 6. He was previously told that nothing could be done to correct the very severe supination deformity of the forefoot and equinovarus malunion of his ankle arthrodesis. (C1), Note the anteroposterior forefoot appearance on this lateral preoperative radiograph. (C2), At the end of correction, the lateral radiograph appears normal.

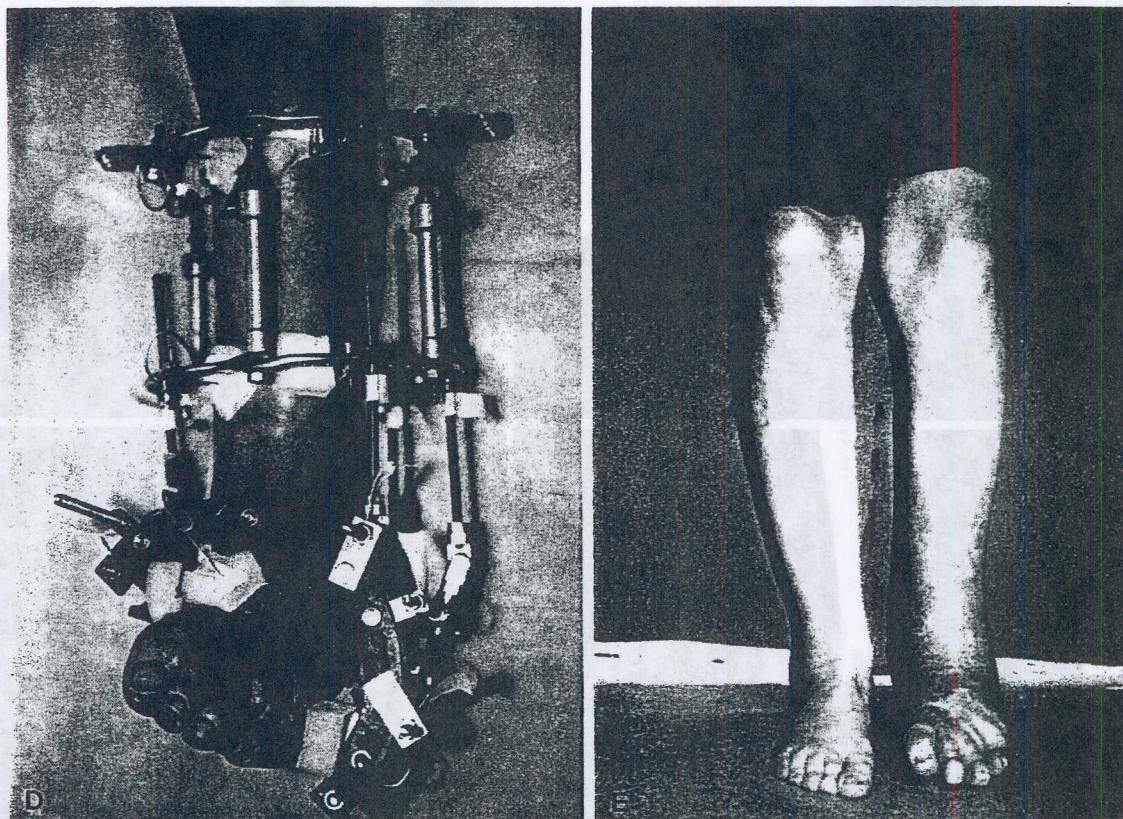


FIGURE 31–29 *Continued* (D), The deformity was corrected through a midfoot osteotomy and a supramalleolar osteotomy in combination. The foot was lengthened and derotated through the forefoot osteotomy, which went across the cuboid and cuneiforms. The equinovarus deformity was corrected and lengthening of 4 cm was achieved through the supramalleolar osteotomy. (E), The final clinical appearance of this man's foot, demonstrating the complete correction of the varus and the supination. (Courtesy of Dror Paley, M.D.)

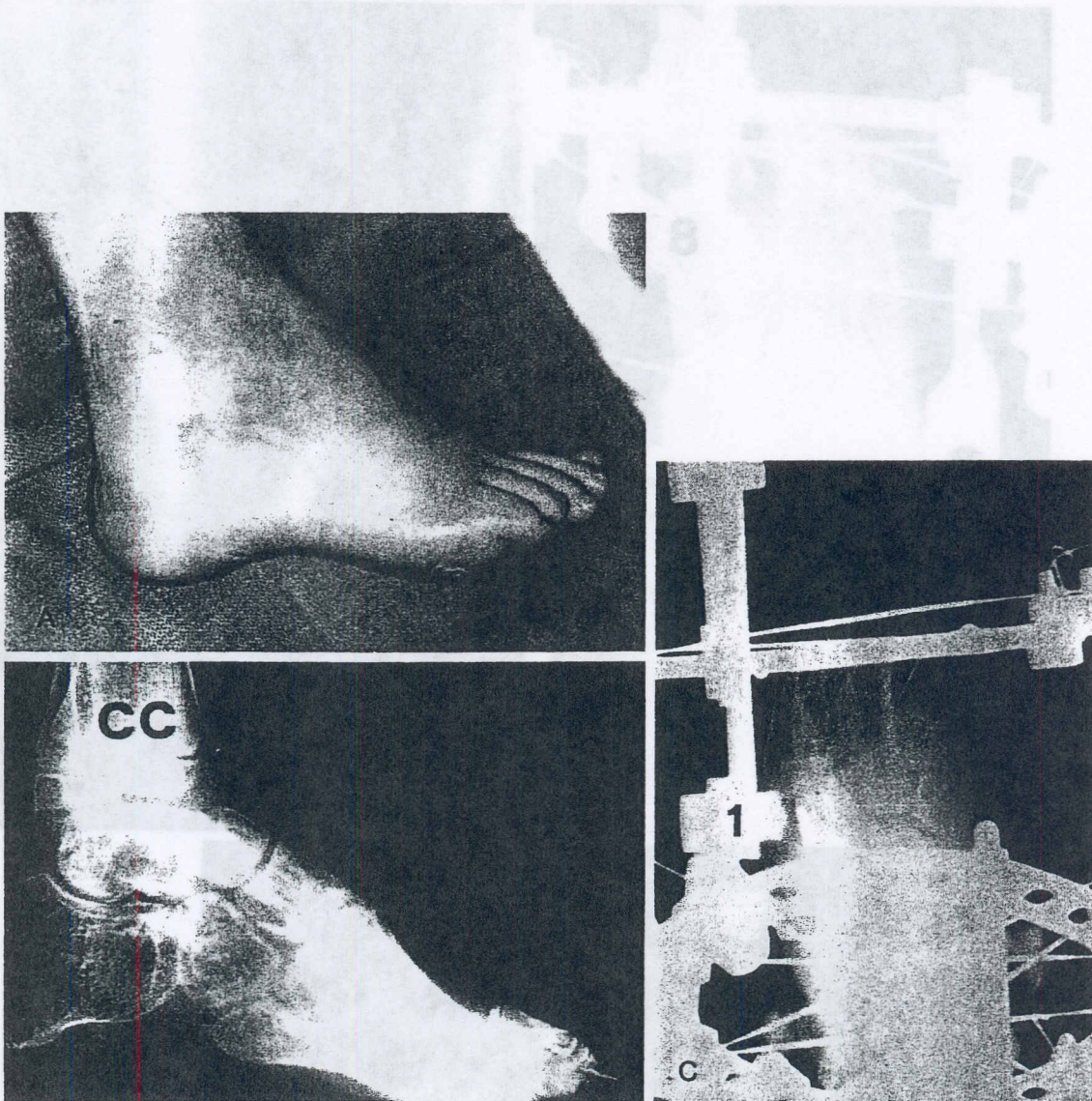


FIGURE 31-30. (A and B), Preoperative photograph and radiograph demonstrating forefoot cavus secondary to a previously treated clubfoot deformity. (C), An osteotomy was performed across the cuboid and cuneiforms. Because of the lack of constraint, the distraction force led to separation of the adjacent joints. The osteotomy never separated.

FIGURE 31-30 Continued (D). The patient was placed in a cast with the foot in a plantar flexed position. At the end of the cast, the foot is plantar flexed and longer. (E) Because of the abnormal growth in the foot from previous activities and surgery, the patient developed a separation of the foot 3 years later. (Courtesy of Gray Pines, M.D.)

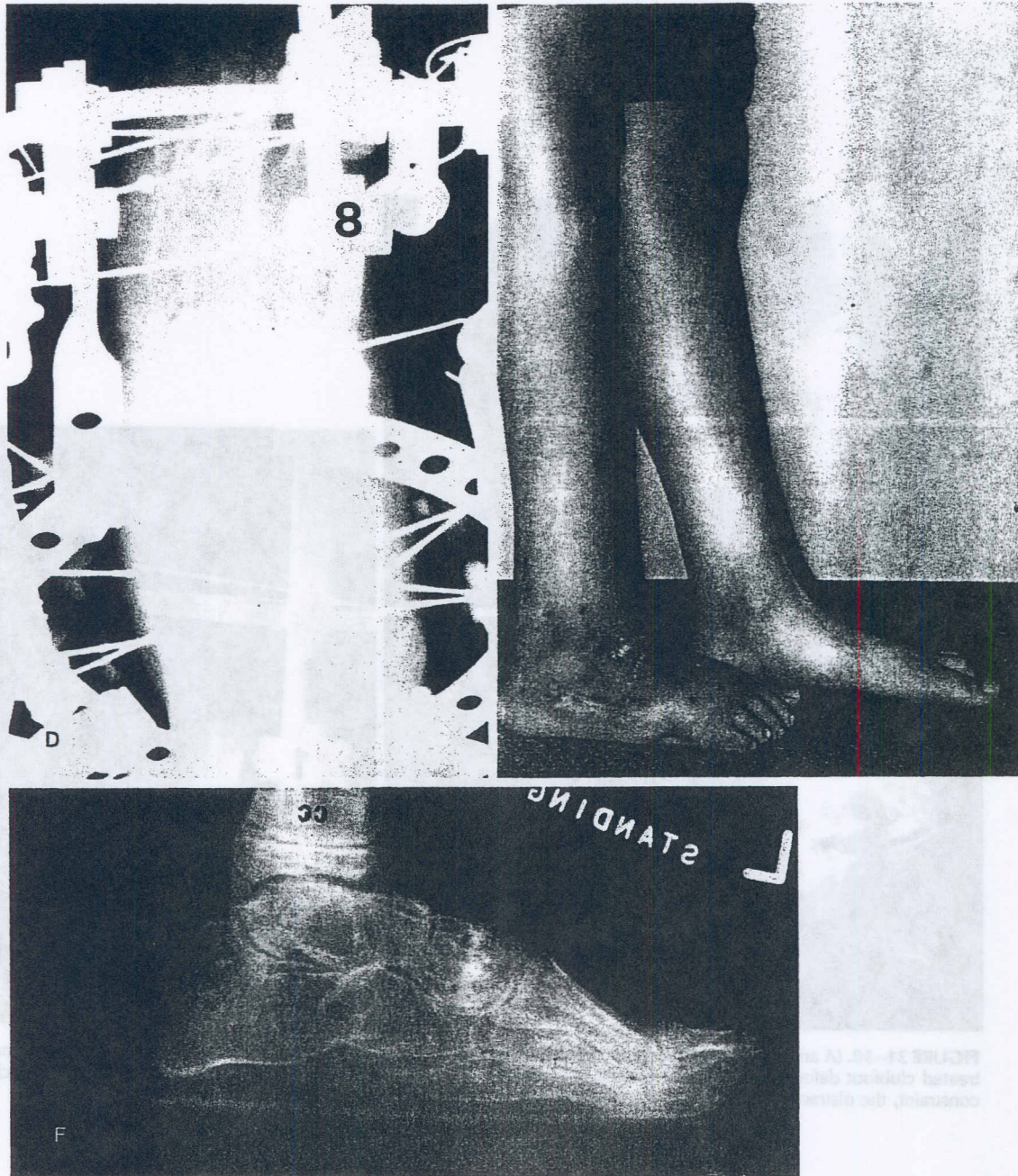


FIGURE 31-30 Continued (D), Therefore, one wire on each side of the osteotomy was inserted to concentrate the forces across the osteotomy and to lock the adjacent joints. (E), At the end of the correction, the foot is plantigrade and longer. (F), Because of the abnormal growth in this foot from previous arthrodeses and surgery, the patient developed a supination deformity of his foot 3 years later. (Courtesy of Dror Paley, M.D.)

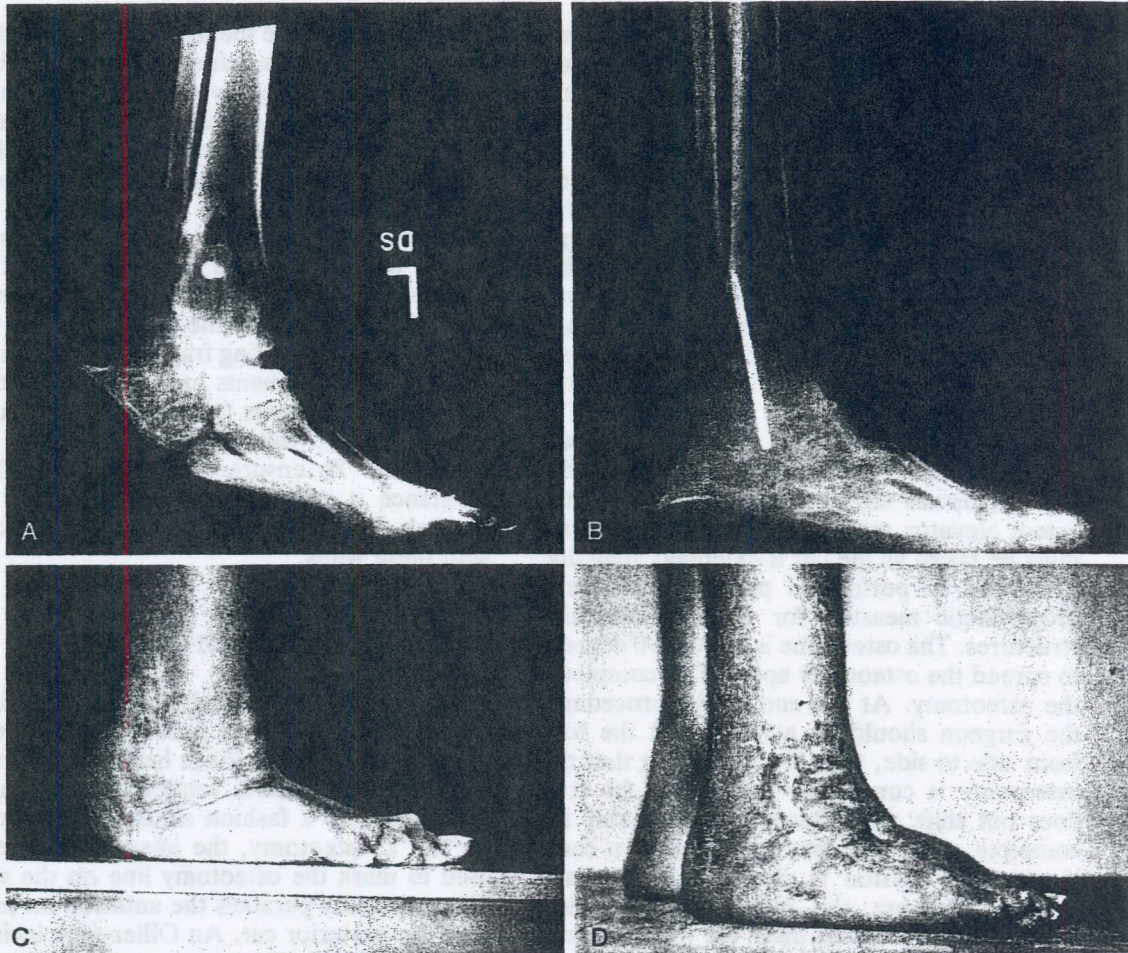


FIGURE 31-31. (A), Severe shortening of the foot following talectomy for a clubfoot deformity. Note the equinus deformity of the heel and the painful nonunion of the tibia and navicular. (B), The foot was osteotomized across the calcaneus and metatarsals. The nonunion was débrided and compressed. The final radiograph after correction of the foot deformity demonstrates the plantigrade foot with re-establishment of the heel and a longer forefoot. (C and D), The appearance of the foot before and after the correction of deformity. This patient also had a simultaneous leg lengthening and widening procedure. (Courtesy of Dror Paley, M.D.)

The corticotomy is performed through two separate incisions. Through a posterolateral incision, the fibula can be cut either by exposing it subperiosteally through a 1- to 2-cm incision or percutaneously using an osteotome. The tibia is cut in a standard corticotomy fashion through a 5-mm anterior tibial crest incision with protection of the medial and lateral periosteum. The osteotomy is completed with a rotational osteoclasis. It is important to ensure that the osteotomy is complete. The osteotomy can be distracted 5 mm to see if it separates. It is easy to mistakenly leave an intact posterior hinge of bone, which would lead to nonseparation of the bone ends.

U-Osteotomy (see Fig. 31-15)

Before the apparatus is applied to the leg, the osteotomy should be performed. Before the osteotomy, a percutaneous Achilles tendon lengthening should be performed for equinus correction. Under tourniquet control, the image intensifier is used to mark the line of the osteotomy on the skin. The anterior half of this line is used for the incision. Care should be taken to identify the sural nerve and to protect it. The peroneal tendons are encountered and can be retracted, or in the case of a rigid foot with no subtalar function and a stiff forefoot, they may be cut. The osteotomy may

be performed using a special curved osteotome or gouge. Alternatively, a 1/2-inch osteotome may be used. Before the cut is made, the position of the osteotome is checked with the image intensifier. Intermittent hammering on the osteotome with radiographic checks is performed. The surgeon must be careful to listen and feel as the osteotome penetrates deeper and must use the image intensifier as needed to confirm if it has exited on the medial side. Alternatively, an incision may first be made on the medial side to decompress the tarsal tunnel and a finger may be placed to feel the osteotome exiting on the medial side. The posterior portion of the osteotomy is performed with a curved osteotome. The overlying soft tissues are elevated only with a periosteal elevator around the lateral wall. Care must be taken as the cut is extended medially. This may be performed partially open as a prophylactic measure for the neurovascular structures. The osteotome is twisted 90 degrees to spread the osteotomy apart. This completes the osteotomy. At the end of the procedure, the surgeon should be able to shift the foot from side to side, thus demonstrating that the osteotomy is completely mobile. If the foot does not shift, the osteotomy is probably incomplete. After the osteotomy has been completed, the incision is closed in a standard fashion. Because the incision was carried straight down to bone, there are no soft tissue flaps, which is important in a foot that has had multiple operations.

The apparatus consists of a proximal block of two rings, as described for the supramalleolar osteotomy. This apparatus is modified if a proximal tibial lengthening is to be performed concomitantly. A foot plate is constructed using a half-ring, two plates with threaded extensions, and another half-ring at 90 degrees to these plates. The angular deformity of the foot should be resolved into one plane and, therefore, one hinge.¹³ Once this hinge direction has been determined, the foot plate can be connected to the tibial ring with a single hinge. Alternatively, the surgeon can ignore one plane of deformity and correct first the equinus deformity and then the varus deformity. The former method allows simultaneous correction of the equinus and varus deformities through the true oblique plane of the deformity. Fixation to the tibia is accomplished with two wires on each ring, with olives appropriately placed relative to the type of angular

correction. Because the majority of corrections are for equinovarus deformity, an olive wire is required anterolaterally on the tibia. An additional olive wire should be placed posteromedially to permit posterior translation of the foot on the tibia if needed. The foot fixation consists of two wires in the calcaneus, two wires in the metatarsals, and, most importantly, one wire in the head or neck of the talus distal to the osteotomy. One wire is needed in the body of the talus, and one wire is needed in the floating fragment of calcaneus. If these bone segments are not transfixed on distraction, the joints (subtalar, talonavicular, and tibiotalar) will separate instead of the osteotomy. To ensure that the path of least resistance is through the osteotomy and not through the joints, the joints must be locked with these wires.

V-Osteotomy (see Fig. 31-18)

As in the U-osteotomy, the first step is to perform the osteotomy before application of the apparatus. For equinus heel corrections, a percutaneous Achilles tendon lengthening is performed. In a fashion similar to that used for the U-osteotomy, the image intensifier is used to mark the osteotomy line on the skin. The osteotomy parallels the anterior cut more than the posterior cut. An Ollier-type incision is generally used. The anterior cut is performed across the calcaneus, the sinus tarsi, and the talar neck. The posterior cut is performed so as to meet with the anterior cut on the plantar surface of the calcaneus. The surgeon may elect to prophylactically decompress the posterior tibial nerve and feel for the osteotome as it exits medially. The osteotome is twisted to complete the osteotomies and spread the osteotomy surfaces apart. A radiograph is obtained at the completion of the osteotomy and before application of the hardware. A temporary Kirschner wire can be inserted into the calcaneus to decrease the bleeding. The apparatus is then applied, with the hinges centered in the right places. It is usually very crowded around the foot and very difficult to connect all the wires and hinges because of the tight spaces. The V-osteotomy requires the maximum in apparatus efficiency to allow for fixation and hinge placement.

The proximal block of fixation on the tibia is prepared in a manner similar to that de-

scribed for the U-osteotomy. Hinges are used between a posterior half-ring, which is connected to the calcaneus, and an anterior half-ring for the forefoot. The forefoot may have a second half-ring over the midfoot. Alternatively, the second level of fixation for the forefoot can be off posts. The hinges are placed relative to the apex of deformity posteriorly and anteriorly. Two transverse wires and one axial half-wire are used in the calcaneus for fixation. Two metatarsal wires and one talar neck wire are used for fixation in the forefoot. The body of the talus and the floating fragment of calcaneus must be transfixed to the tibial ring.

Other Osteotomies

The posterior calcaneal and talocalcaneal neck osteotomies, when used alone, are performed as described for each limb of the V-osteotomy.

The midfoot osteotomy may be performed through one dorsal incision or through one medial incision and one lateral incision. Care must be taken to follow the arch of the foot so as not to exit on the plantar side and risk injuring the neurovascular structures. A subperiosteal elevator may be inserted dorsally and on the plantar aspect of the foot to protect the osteotome. The construct is similar to that used with the talocalcaneal neck osteotomy. One technical pearl is to insert one wire on either side of the osteotomy to lock the talonavicular and calcaneocuboid joints and the midfoot tarsometatarsal joints. If this is not done, distraction will occur through the adjacent joints rather than through the osteotomy. Joints, rather than osteotomies, are usually the paths of least resistance to distraction.

RESULTS

Grill and Franke reported on 10 clubfoot deformities in patients ranging from 8 to 15 years of age.³ The etiologies included neglected or relapsed congenital clubfoot, post-traumatic equinovarus deformity, arthrogryposis, spastic diplegia, and Charcot-Marie-Tooth disease. All of the feet were stiff preoperatively. All were treated by the nonosteotomy distraction technique of Ilizarov. A plantigrade foot was

achieved in all patients, with satisfactory radiographic and clinical results. All of the feet had subtalar stiffness pre- and postoperatively, and the average range of movement at the ankle was 20 degrees. The complications were mostly minor ones, such as pin track infections. One patient required a tendon lengthening for claw-toe. Another patient with an arthrogryptic foot had a relapse because of the lack of postoperative immobilization. The treatment was repeated, and a good result was achieved. All patients were satisfied with their results and were for the first time able to wear normal shoes. The period of distraction ranged from 4 to 10 weeks. The device was then maintained in place for an additional 8 to 10 weeks, after which patients were put into below-knee plaster casts for 3 to 4 months. The mean time to follow-up in this study was 3.3 years (range, 6 months to 6 years).

I reported the results of osteotomy treatment in 23 patients with 25 severely deformed feet who were treated with Ilizarov distraction osteotomies.¹⁵ Nineteen of the 25 feet had had multiple operations for recalcitrant leg and foot deformities. Pre-existing foot stiffness was present in all cases. There were 10 males and 13 females. The patients' ages ranged from 6 to 63 years, with a mean age of 25 years. A wide range of foot deformities of different etiologies were treated. The corrective osteotomies included 13 supramalleolar osteotomies, two U-osteotomies, two V-osteotomies, two talocalcaneal neck osteotomies, five posterior calcaneal osteotomies, two midfoot osteotomies, and one panmetatarsal osteotomy. The treatment included lengthening of the leg in 20 of the limb segments. Lengthening of the foot was carried out in five cases. Other associated treatments included leg widening for cosmesis in seven cases, distraction of forefoot deformities in four cases, and tibial or femoral mechanical axis realignment (or both) in three cases.

The mean treatment time was 6.4 months (range, 3 to 11.3 months). In most cases, the treatment time was dependent on the consolidation of the tibial limb lengthening segment rather than on the foot osteotomy. All but seven patients experienced one or more minor to major complications (20 complications in 18 feet). Pin track infection of a superficial nature occurred in at least one pin in every patient at some time during their treatment. This rarely caused problems and was easily treated by

local measures and oral antibiotics. Three patients had deep soft tissue infections of their pin sites, requiring pin removal and operative intervention for wire insertion or débridement. One patient developed osteomyelitis and septic arthritis of the fifth metatarsophalangeal joint after a pin cut out of the metatarsal shaft into the joint. This required two serial débridements and healed uneventfully. This patient simultaneously developed an abscess on the lateral wall of the calcaneus in a pin track. Débridement and the use of antibiotics led to complete resolution of both infections.

The next most common problem was failure of separation of the osteotomy. This occurred in nine cases. The cause was incomplete surgical osteotomy in three cases and premature consolidation due to an incorrect mechanical construct in six cases. The typical example that led to an incorrect construct was lack of one of the locking wires. The distraction led to diastasis of the adjacent joint instead of the osteotomy.

Acute tarsal tunnel syndrome developed within 24 hours of the surgery in two patients. In one, it was discovered in the recovery room. The patient was immediately returned to the operating room, and the tarsal tunnel was decompressed. The patient reawoke with completely normal sensation. The second case of tarsal tunnel syndrome did not develop until the first postoperative day and was treated by immediate decompression. Full recovery of neuromuscular function occurred over the next 3 months. In both cases, there was edema but no hemorrhage in the tarsal tunnel.

Toe contractures were common, especially with corrections of equinus and cavus deformities and with foot lengthenings. Most toe contractures resolved, with the exception of three cases. Two of these were treated with percutaneous release during or at the end of treatment. In one case, the patient refused further treatment, although he remained symptomatic with clawed toes. This patient was the one whose tarsal tunnel syndrome took 3 months to resolve. Possibly an element of neuromuscular dysfunction contributed to the toe clawing, in addition to the abnormal muscle tension of the foot lengthening. Prophylaxis of toe contractures is carried out with toe slings and elastic bands. More recently, I have been using a 1-mm wire inserted across the base of the distal phalanx and connected to the apparatus to prevent contracture of the toes. Since

I started using this method, I have not had any further difficulty with toe contractures during foot lengthening.

There were several wire problems not related to pin track infections. In one patient, the wires began to cut out of the heel, and insertion of an additional wire was required. In another patient, several wires broke at different times. This patient was paraparetic and had an anesthetic foot. Because the usual instructions are for weight bearing as tolerated to and including full weight bearing, this patient literally walked full weight bearing without support throughout the treatment. This led to repeated wire fractures. Fortunately, reinsertion of wires was facilitated by his anesthetic leg and foot and did not require a return to the operating room.

One patient with a supramalleolar lengthening and deformity correction developed a buckle fracture due to premature removal of the apparatus. Because the treatment was bilateral and the buckle fracture occurred on only one side, this patient was left with a 1.5-cm leg length discrepancy.

One patient with multiple osteochondromas developed a nerve injury due to the proximal tibial osteotomy. The distal tibial supramalleolar osteotomy did not lead to any complications. Fortunately, the nerve injury resolved.

There was one case of skin breakdown from a talocalcaneal neck re-osteotomy following a premature consolidation. This healed uneventfully after the wound was left open.

None of the previously mentioned complications, with the exception of the one persistent toe contracture and the minor leg length discrepancy, led to any permanent residual effect on the patient, and although they complicated the treatment, they did not obstruct the treatment goals. In total, 19 secondary surgical procedures were carried out in 13 patients to treat problems and complications that arose secondary to the foot deformity correction, and two additional secondary procedures were carried out to treat complications of the proximal tibial osteotomy.

At the time of fixator removal, 24 feet were plantigrade. At follow-up, only 22 feet were plantigrade. One foot was not plantigrade at the time of fixator removal; this problem was due to an unrecognized varus deformity (5 degrees) of the heel. The leg length discrepancy and midfoot cavus were treated successfully; only the untreated varus remained. A

supramalleolar osteotomy through the ankle arthrodesis malunion was performed to correct the varus. There was one recurrent deformity due to an unrecognized ball-and-socket ankle joint. This patient had a preoperative post-traumatic ball-and-socket ankle joint with a varus heel deformity, which was treated by a posterior calcaneal osteotomy. With valgus distraction, the deformity corrected by eversion of the unconstrained ball-and-socket ankle joint instead of by the opening of a wedge in the calcaneal osteotomy. This could have been avoided by the use of wires in the talus. This patient will require a second osteotomy.

These two patients were considered to have unsatisfactory results despite the significant improvement in pain and gait in both because of persistent foot deformity at follow-up. Both had successful elimination of length discrepancy and leg deformity. Finally, one boy who was treated successfully for postclubfoot cavus developed a mild supination of the forefoot due to previous arthrodeses of the foot. This secondary deformity was unrelated to the distraction treatment, and the result was graded as satisfactory.

Pain was a preoperative complaint in only eight patients. Postoperatively, three patients complained of pain: the patient with a partial recurrence of deformity complained of pain; one patient with successful resolution of equinovarus complained of arch pain; and one patient with a rocker-bottom deformity complained of ankle pain.

Gait was improved in all patients. The patient with a stiff rocker-bottom foot (mentioned earlier) complained of a stiff foot gait at follow-up. This patient had insisted on a foot lengthening in addition to the deformity correction. The final result was feet of equal length and a stiff plantigrade foot with a longer platform to step over. Although a plantigrade foot was achieved, her flatter, longer forefoot applied more stress to her abnormal ankle than was applied preoperatively, resulting in pain. The result was therefore graded as unsatisfactory despite her successful foot deformity correction and 9 cm of lengthening. In total, there were 21 satisfactory (84 percent) and four unsatisfactory (16 percent) results at the time of follow-up. It should be noted that foot stiffness was difficult to assess in this group of patients because the majority had had significantly stiff feet before correction (19 of 25 feet). Pre-existing ankle, subtalar, and midfoot

range of motion was preserved when it was present preoperatively; however, toe motion was decreased in two patients who had foot lengthening. Radiologic loss of joint space was noted in the midfoot joints of two asymptomatic patients. Its significance remains unclear.

DISCUSSION

The Ilizarov method is well known for its limb lengthening and correction of long-bone deformities. The correction of complex foot deformities using specialized distraction osteotomies is less well recognized.^{12, 13, 14} Conventional treatment of complex foot deformities has many limitations. First and foremost is the limitation imposed by the presence of neurovascular structures, which are acutely placed on stretch. The exposure needed places important collaterals at risk in an already compromised circulation. Re-exploration and osteotomy of these feet is therefore fraught with complications and is a high-risk procedure. The second limitation is that of length. Conventional osteotomies need to sacrifice foot and leg length to achieve correction of significant angular deformities. This further shortens an already short leg or foot. Conventional osteotomies often resect, arthrodesis, or cross normal foot joints.^{4, 10} This further stiffens an already stiff foot.

The Ilizarov method offers the advantages of being minimally invasive and using minimal dissection; therefore, it carries a decreased risk of neurovascular and soft tissue injury and infection. This is particularly advantageous in the foot that has had multiple operations. The Ilizarov method is also not limited by the magnitude of the deformity, and it relies on bone regeneration rather than bone resection. Therefore, there is no need to shorten the leg or foot. Correction can be performed either through the bone, joint, or arthrodesis. The choice of method depends on the location and type of deformity. The Ilizarov method allows a comprehensive approach to foot deformity correction by treating not only the foot deformity but also the associated tibial deformities, length discrepancies, and even thin calves. Foot lengthening, although it is rarely indicated, can be combined with some of the foot osteotomies.^{6, 7, 16} Because no length is sacrificed in deformity correction, a significant amount of foot length is regained simply by

deformity correction with an opening wedge technique. Although conventional surgery relies on three-dimensional methods that must be accomplished within the time frame of the operation, the Ilizarov technique is four dimensional because time is one of the variables that can be adjusted. The manipulation of the three-dimensional deformity in time, therefore, provides a safer method of foot deformity correction in many instances.

The disadvantages of the Ilizarov technique are obviously those of an external fixation device and in particular those of pin site problems. In addition, the Ilizarov method requires a lengthy treatment time with prolonged joint immobilization and is frequently associated with mild to moderate pain during the distraction period.

Functional loading, including full weight bearing as tolerated, is permitted during treatment. This helps counteract the prolonged joint immobilization. The patients reported on in both my¹⁵ and Grill and Franke's³ series had some of the most difficult and complex foot deformities that present to the orthopaedic surgeon. Whereas complex problems demand complex solutions, simple problems demand more simple solutions. Therefore, for more simple foot deformities, conventional methods may be preferable. Nevertheless, even for simple foot deformities, the Ilizarov solution offers the advantage of minimal invasiveness.

Furthermore, the Ilizarov method offers one major advantage over standard conventional treatments in that it is adjustable even after an acute correction is performed. Achieving a perfectly plantigrade foot in the operating room is not a simple task, whether with an osteotomy or an arthrodesis. With the circular external fixator, the desired correction can be obtained either rapidly in the operating room, or gradually postoperatively, and the surgeon can ensure that the patient is comfortable with the foot position before accepting it as the final position. With greater adjustability, there is little excuse for not achieving an absolutely plantigrade foot that the patient is happy with.

Despite all these advantages, the main limitation of this technique is still the foot with which one starts. A stiff equinovarus foot that is corrected into a plantigrade position becomes a stiff plantigrade foot. Frequently, patients' expectations do not take this into consideration, and patients may be disappointed

that their foot, which is now aesthetically more pleasing and functionally plantigrade, does not perform like a normal foot. Therefore, before the treatment of any complex foot deformity is started, it is important to convey to the patient a realistic sense of what the foot deformity correction will accomplish, what the foot will be like in the corrected position, and what its limitations will be. Careful attention to the indications for treatment and an appropriate choice of construct and osteotomy are essential. Compared with the application of the Ilizarov method to other limb segments, the application to the foot has a much steeper learning curve. Application to the foot should probably be undertaken only by surgeons who have experience with this method on long bones. When properly planned and applied, this method, although associated with frequent complications, can still accomplish the goals of treatment in almost all cases.¹⁴

References

1. Carroll N: Clubfoot. In Morrissey R (Ed): Lovell and Winter's Pediatric Orthopedics, 3rd Ed. Philadelphia, JB Lippincott, 1990, pp 927-956.
2. Grant AD, Atar D, Lehman WB: Ilizarov technique in correction of foot deformities: A preliminary report. *Foot Ankle* 11:1-5, 1990.
3. Grill F, Franke J: The Ilizarov distractor for the correction of relapsed or neglected clubfoot. *J Bone Joint Surg*. 69B:593-597, 1987.
4. Herold HZ, Torok G: Surgical correction of neglected clubfoot in the older child and adult. *J Bone Joint Surg* 55A:1385-1395, 1973.
5. Ilizarov GA, Shevtsov VI, Kuzmin NV: Results of treatment of equinus foot deformity. *Ortop Travmatol Protez* 5:46-48, 1983.
6. Ilizarov GA, Shevtsov VI, Kalyakina VI, Okutov GV: Foot form shaping and lengthening methods. *Ortop Travmatol Protez* 1:49-51, 1983.
7. Ilizarov GA, Shevtsov VI, Shestakov VA, Kuzmin NV: The Treatment of Foot Deformities in Adults by the Ilizarov Transosseous Osteosynthesis. Methodological Recommendation Book. Kurgan, Russia: Kurgan Internal Publication, 1987.
8. Istomina IS, Kuzmin VI: Treatment of equino-excavato-varus deformation of the foot in adults with a hinge distraction apparatus. *Ortop Travmatol Protez* 3:19-22, 1990.
9. Kovalev YV, Gorlov GA: Bone and musculotendinous surgery for treatment of recurrent and residual congenital clubfoot. *Ortop Travmatol Protez* 7:37-40, 1986.
10. Lambrinudi C: New operations on drop foot. *J Bone Joint Surg* 15:193-200, 1927.
11. Lehman WB, Paley D, Atar D: Operating Room Guide to Cross Sectional Anatomy of the Extremities and Pelvis. New York, Raven Press, 1989.

12. Paley D: Current techniques of limb lengthening. *J Pediatr Orthop* 8:73-92, 1988.
13. Paley D: The Principles of Deformity Correction by the Ilizarov Technique. Technical Aspects. *Tech Orthop* 4:15-29, 1989.
14. Paley D: Problems, obstacles, and complications of limb lengthening by the Ilizarov technique. *Clin Orthop* 250:81-104, 1990.
15. Paley D: The correction of complex foot deformities using Ilizarov's distraction osteotomies. *Clin Orthop* 1993, in press.
16. Rojkov AV, Startzev TE, Batenkova GI, et al: Methodology of reconstruction of short foot stumps with the help of distraction methods. *Ortop Travmatol Protez* 5:48-52, 1983.
17. Umhanov HA: Method of apparatus correction in orthopedic treatment of children with the cerebral spastic palsies.
18. Zavialov PV, Stabskaya EA: Treatment of the congenital clubfoot by the distraction-compression method. *Ortop Travmatol Protez* 2:41-44, 1978.

