

# 5

## Progress in and from Limb Lengthening

**Dror Paley, MD, FRCSC**

*Director, Paley Advanced Limb Lengthening Institute, St. Mary's Hospital, FL*

### ► INTRODUCTION

In 1988, soon after I started my career as a limb lengthening surgeon, my first article on limb lengthening entitled *Current Techniques in Limb Lengthening* was published in the *Journal of Pediatric Orthopedics*.<sup>1</sup> At that time I did not imagine that this would go on to become number 19 of the 25 most cited articles in pediatric orthopedics.<sup>2</sup> Twenty-five years later, I find myself sitting down to write the sequel “Progress in and from Limb Lengthening”.

Surgical limb lengthening dates back to the turn of the 20th century with the publication by Codivilla<sup>3</sup> in 1905. Over the first half of the 20th century, the lengthening devices ranged from the traction Thomas splint device of Codivilla, to various bed-mounted and semi-portable external fixation devices. The early limb lengtheners<sup>4–10</sup> employed distraction osteogenesis to fill the distraction gap produced by their fixators. It was not however until the 1950s and 1960s that the biology of distraction osteogenesis became understood. This was largely due to Ilizarov and his group in Kurgan, USSR. His pioneering basic science and clinical work demonstrated that distraction osteogenesis was primarily an intramembranous bone formation technique, in which a pluripotential fibrous interzone which forms in the middle of the distraction gap between two bone ends that are gradually distracted apart. Longitudinal bony trabeculae-looking like opposing stalactites and stalagmites meet at this interzone and are parallel to the direction of distraction. The trabeculae are lined with osteoblastic cells that take their origin in the pluripotential cells of the “fibrous interzone”. In between these trabeculae run longitudinally oriented vascular channels, making this “regenerate” mass a very vascular tissue. Ilizarov showed that under ideal, stability, rate, and rhythm of distraction, and preservation of the vascularity of the bone and its surrounding tissues, the regenerate bone would “directly” form as

described above from this fibrous interzone. When there was more movement or poorer vascular preservation or too rapid distraction, cartilage or fibrous tissue would form. Complete failure of tissue formation could also occur resulting in cystic degeneration. The biology of distraction osteogenesis was later investigated and corroborated by Aronson et al.<sup>11-14</sup> and Yasui et al.<sup>15-17</sup> Based on their biologic work and clinical correlation, Ilizarov outlined a series of principles to optimize distraction osteogenesis. These included: rate (between 0.5–1 mm/day); rhythm (usually  $\frac{1}{4}$  mm/4 times a day); low energy osteotomy with preservation of periosteum and marrow tissues; no initial diastasis or displacement of the bone ends; latency period prior to distraction; metaphyseal better than diaphyseal level for osteotomy; and stable fixation.

Failure to follow Ilizarov's principles, frequently lead to failure of bone formation. This was the case with the Wagner technique. Wagner's technique involved an open high energy diaphyseal osteotomy, cutting through the periosteum and endosteum; initial 1–1.5 cm diastasis of the bone ends; and a distraction rate of 1.5 mm per day. The fixation was with a portable monolateral external fixator that had rotation points at each end that could bend with loading. Failure of bone formation was common and expected. Bony union was achieved by bone grafting the distraction gap. A plate was applied to allow removal of the external fixator. While this technique became the standard in the West, the Ilizarov method dominated in the East behind the Iron Curtain. It seemed that all that was learned in the first half century was lost. This did not change until 1981 when Ilizarov was invited to Italy. Europe adopted and adapted his principles whether using his original fixator or through a handful of new devices including: the Orthofix and Monotube monolateral external fixators and the Monticelli-Spinelli, Sequoia, Lima and Fixano circular external fixators. Even in his own country new devices arose and were used to apply his principles and methodology including: Volkov-Oganisyan, Gudushauri, Wasserstein, and Kalberns.

In addition to his now well-known principles Ilizarov introduced new methodologies for distraction: bilateral, contralateral and ipsilateral lengthening for dwarfism, bifocal lengthening, lengthening with simultaneous deformity correction, distraction of nonunions, bifocal treatment of nonunions with compression and lengthening at a separate site, bone transport, bone widening, soft tissue transport, articulated distraction of joints for contracture and arthritis, etc. These methods that were unknown to the West prior to the 1980s are now known around the world. This occurred secondary to the introduction of the Ilizarov method through Italy to Europe in 1981 and to North America by Dr. Dror Paley in 1986. The Richards Company (now Smith and Nephew), played a pivotal role in the introduction of the Ilizarov method all around the world. Over the course of the next decade these methodologies will spread to every part of the world.

Progress in limb lengthening over the past 25 years can, therefore, be divided into three parts: (1) Ilizarov's methodology learning curve, (2) Byproducts and (3) New products.

### **Ilizarov's methodology learning curve**

As noted above, since the 1980s limb lengthening with circular and monolateral external fixators applying Ilizarov's principles has allowed us to successfully lengthen the upper and

lower limb bones of children and adults. Lengthening has been successfully applied unilaterally for equalization of limb length or bilaterally for short stature for a wide variety of indications. These include congenital, developmental, post-traumatic, and dysplasia. While the principles of lengthening remain the same, each condition poses different considerations that have to be addressed to make the treatment successful.

To apply the limb lengthening method one must consider not only the discrepancy or goal of lengthening, but also has to evaluate the associated deformities of rotation, angulation, and translation. One then has to choose whether these can or need to be corrected and whether to combine their correction with, before, or after the lengthening. The joint stability of the joint proximal and distal to the lengthening segment should be evaluated and considered. Lengthening for congenital femoral deficiency (CFD), for example, can lead to subluxation or dislocation of the knee and/or hip joints. The joint may need to be spanned at the time of lengthening or preoperatively stabilized (e.g., pelvic osteotomy for coverage) prior to lengthening.

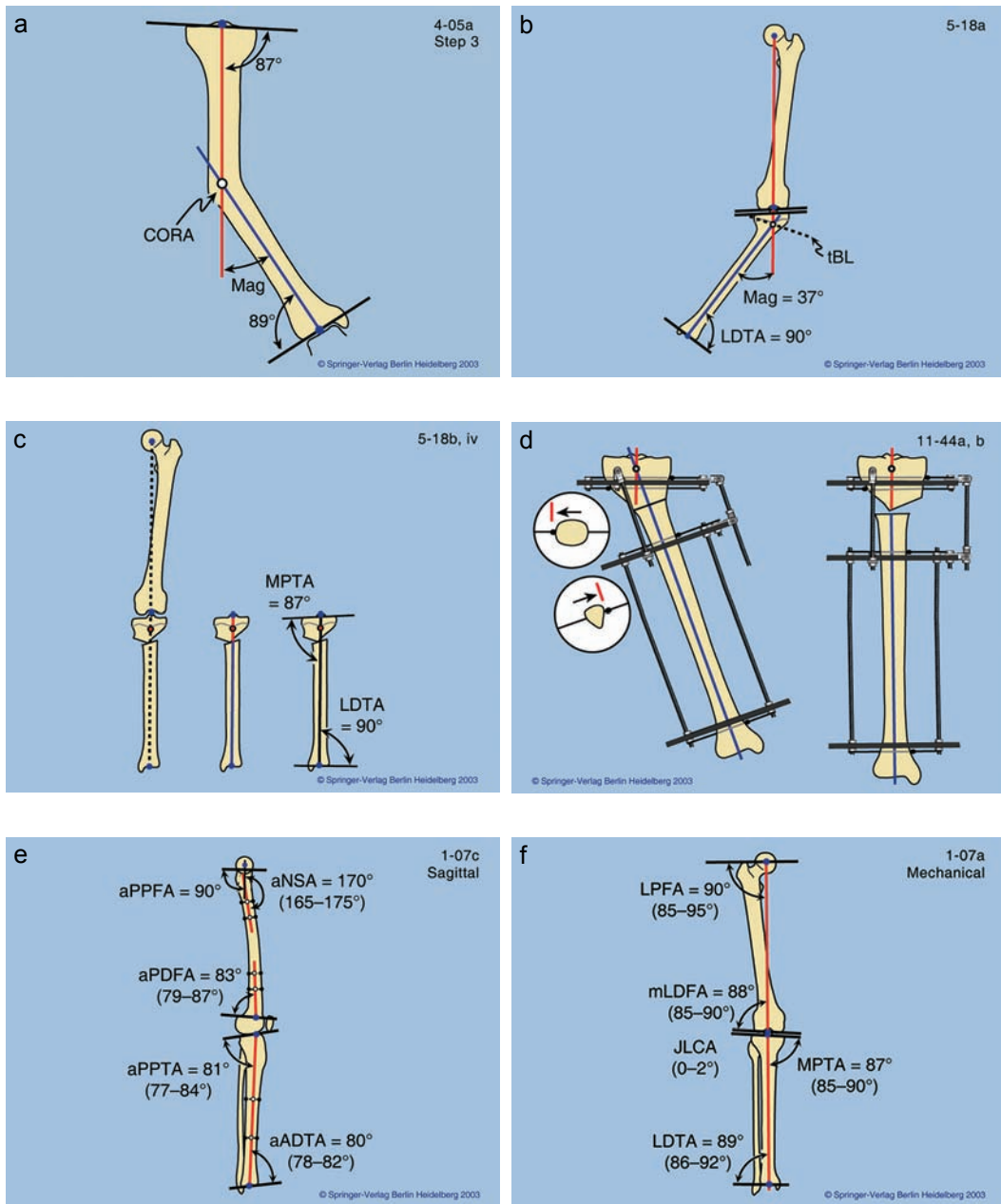
Each pathology has its own techniques and learning curve. Bone defects can be treated by bone transport or by shortening of the defect combined with lengthening at another site. Nonunion treatment depends on the type of nonunion. Stiff hypertrophic ones lend themselves to distraction, while mobile atrophic ones are best treated open with bone grafting and lengthening through a separate osteotomy.

The learning curve for the techniques that Ilizarov developed between 1951 and 1981 was learned by surgeons worldwide as they applied these techniques using the Ilizarov or other devices. The obstacles and challenges they encountered on the way lead to what I call the *byproduct* and *new product* advances of the last 25 years. I shall focus the rest of this chapter to discuss these advances. I refer the reader to the plethora of publications (articles, book chapters, books, videos, etc.) on the Ilizarov methodology, all of which cannot be referenced here. While the devices and even the techniques have changed significantly, they are all still based on the biologic principles established by Ilizarov.

## Byproduct advances of the past 25 years

### 1. Deformity analysis and nomenclature

When I first started applying the Ilizarov method with its various hinges, rotation, and translation attachments, I was puzzled by where to apply the hinge especially for metaphyseal deformities. The search for the correct location of the hinge, led me to develop what is now referred to as CORA planning. The CORA (center of rotation of angulation) is the point where the proximal and distal axes of the bone intersect (Fig. 5.1a). To define these axes, especially for non-diaphyseal deformities, required an understanding of frontal and sagittal plane alignment and joint orientation that did not exist at that time. This led to a new nomenclature that has been adopted worldwide defining the mechanical and anatomic axes and their related joint orientation angles (LDFA, MPTA, LPFA, LDFA in the frontal plane Fig. 5.1b, and PPTA, PDFFA, ADFA in the sagittal plane Fig. 5.1c). It established a set of osteotomy rules based on sound geometric principles. It introduced the concept of plane of deformity



**Figure 5.1**

(a) The center of rotation of angulation (CORA) is the intersection of the proximal and distal axis lines. (b) The CORA of a proximal metaphyseal varus deformity is marked. (c) If the osteotomy is placed distal to the CORA but the correction occurs around an axis going through the CORA then the osteotomy will angulate and translate. (d) The CORA method was originally developed to accurately determine the level of the Ilizarov hinge. (e) Joint orientation angles in the frontal plane. (f) Joint orientation angles in the sagittal plane.

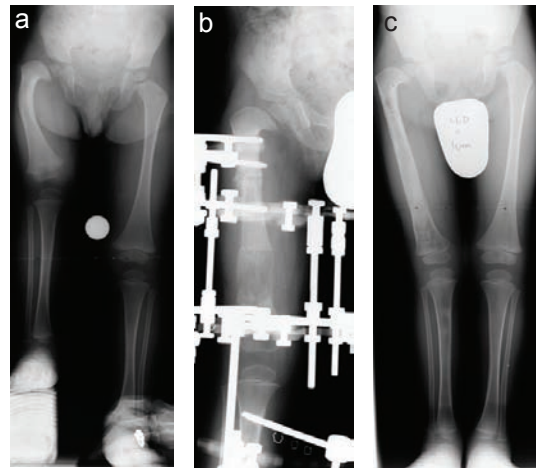
and six-axis deformity correction. Current orthopedic deformity nomenclature, theory, and practice, is all a *byproduct* of the Ilizarov hinge. Perhaps the best reference for this is the book I authored, *Principles of Deformity Correction*.<sup>18</sup>

## 2. Age of lengthening surgery

In 1986 when I returned after studying with Ilizarov and with the Italians, the conventional wisdom was that elective lengthening for leg length discrepancy should not be performed prior to age 6. No objective reason was given for this. Subjective rationale included: concern regarding growth inhibition in young children; it is hard to discern if an infant is crying from pain or from other causes; joint or growth plate damage would occur; technically too small and difficult. Parents of children born with large congenital limb length discrepancy pushed for earlier treatment had to be told that nothing should be done prior to age 6 for all the reasons mentioned above. In 1990, I had the privilege to meet Dr. BB Joshi from Mumbai, India. He was applying external fixators for the correction of clubfoot in children under 1 year of age. He argued against the conventional wisdom and encouraged me to start lengthening after age 1. Having used the Ilizarov device at this age for conditions such as congenital pseudarthrosis of the tibia, I began lengthening in infants as young as 14 months of age for fibular hemimelia (FH) and soon 2 years of age for CFD (Fig. 5.2a–c). Subsequent study of this group of patients demonstrated that growth inhibition did not occur for femoral lengthening in infants irrespective of the amount of lengthening (up to 8 cm) nor did it occur for tibial lengthenings less than 5 cm.<sup>19</sup> Growth inhibition occurred with combined femur and tibia lengthening and with tibial lengthening over 5cms. Interestingly one-third of femurs demonstrated growth stimulation. Parents had no difficulty knowing when their child was in pain and there was not damage to the growth plate or joint cartilage. Lengthening in toddlers was a *byproduct* of learning how to treat CFD and FH in older children by the Ilizarov method.

## 3. Prediction of limb length discrepancy (LLD), timing of epiphysiodesis and hemiepiphysiodesis, and stature

With improved methods of limb lengthening, accurate prediction of LLD at maturity was required. The existing methods of Anderson and Green and Moseley were cumbersome



**Figure 5.2**

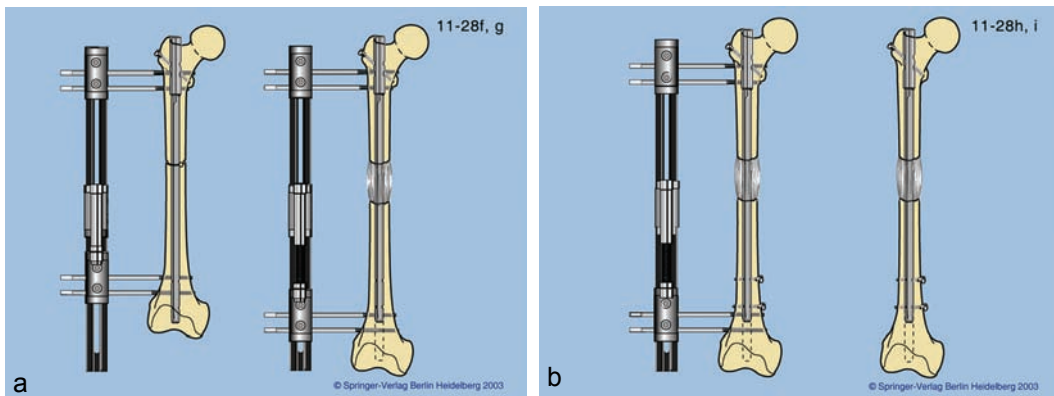
(a) A 2-year-old boy with congenital femoral deficiency and an 8-cm leg length discrepancy. (b) Lengthening of the congenitally short femur with an Ilizarov device at age 2. (c) After 7 cm of lengthening the leg lengths are almost equal.

and time consuming. A quicker, simpler accurate method was needed. In 1997 Paley developed the Multiplier method which was published in 2000.<sup>18,20</sup> This method recognized that a coefficient could be calculated for each age to represent the reciprocal of growth remaining. That coefficient was independent of percentile, race, nationality, and generation. For the lower extremity the coefficients (multipliers) for the femur, tibia, and foot height were the same. Therefore a single set of multipliers could be used to determine bone or limb length. Formulas designed around these multipliers allow for calculation of limb length and LLD at skeletal maturity or at any age (forward or backwards in time), as well as timing of epiphysiodesis. The accuracy of prediction was also tested<sup>21,22</sup> and found to be accurate to less than 1 cm for both epiphysiodesis and LLD. Multipliers were also calculated for height, foot length, upper extremity, and fetal bone growth. They can be used for predictions of LLD from in utero measurements,<sup>23</sup> prediction of height,<sup>24</sup> or foot length<sup>25</sup> during childhood. Upper extremity multipliers can be used for LLD and epiphysiodesis planning the same as in the lower extremity.<sup>26</sup> A single X-ray's measurements are sufficient for congenital deformity LLD prediction. For developmental LLD two points in time are required. The Multiplier method is a useful tool to complement the surgical techniques and decision making for children treated for LLD. More recently two apps have made this even easier to do (Paley Growth and Multiplier). The Multiplier method was a byproduct of the need for accuracy and simplicity in limb lengthening.

#### 4. Lengthening over nails (LONs), lengthening and then nailing (LATN), and lengthening over plates (LOPs)

The external fixator has been the gold standard of limb lengthening for over a century. The discomfort of having open pin sites, the tethering of the underlying muscles, chronic pin infections, pin loosening, etc., all make these devices unappealing to both the patient and the surgeon. We tolerate the use of these devices as a necessary means to an end; they get the job done and the patient achieves the goals of treatment. The longer the treatment with the external fixator the less well they are tolerated. The external fixation time for lengthening depends on the combination of the distraction phase (which includes the latency period) and the consolidation phase. The fixator is removed after the consolidation phase. In children the external fixation time is typically 1 month per cm. In adults, the average is 2 months per cm.<sup>27</sup> While there was no alternative to the external fixator as a lengthening device efforts to reduce the external fixation time have focused on replacing the external fixator with some other fixation during the consolidation phase. Wagner applied a plate at the end of the distraction phase and removed the external fixator.<sup>28</sup> Wasserstein inserted a cortical allograft and thin rod to support the distraction gap.<sup>29</sup> Bost and Larsen introduced the idea of a guiding the lengthening with a Rush rod in 1956.<sup>10</sup> In 1990, I inserted a locked intramedullary nail and applied an external fixator at the same time. The idea was to lengthen over a nail (LON) and then lock it at the end of the distraction phase and remove the external fixator (Fig. 5.3a,b). Paley et al. published our first series of LON in 1993 and 1997.<sup>30,31</sup> Two years later we tried to do this technique by inserting





**Figure 5.3**

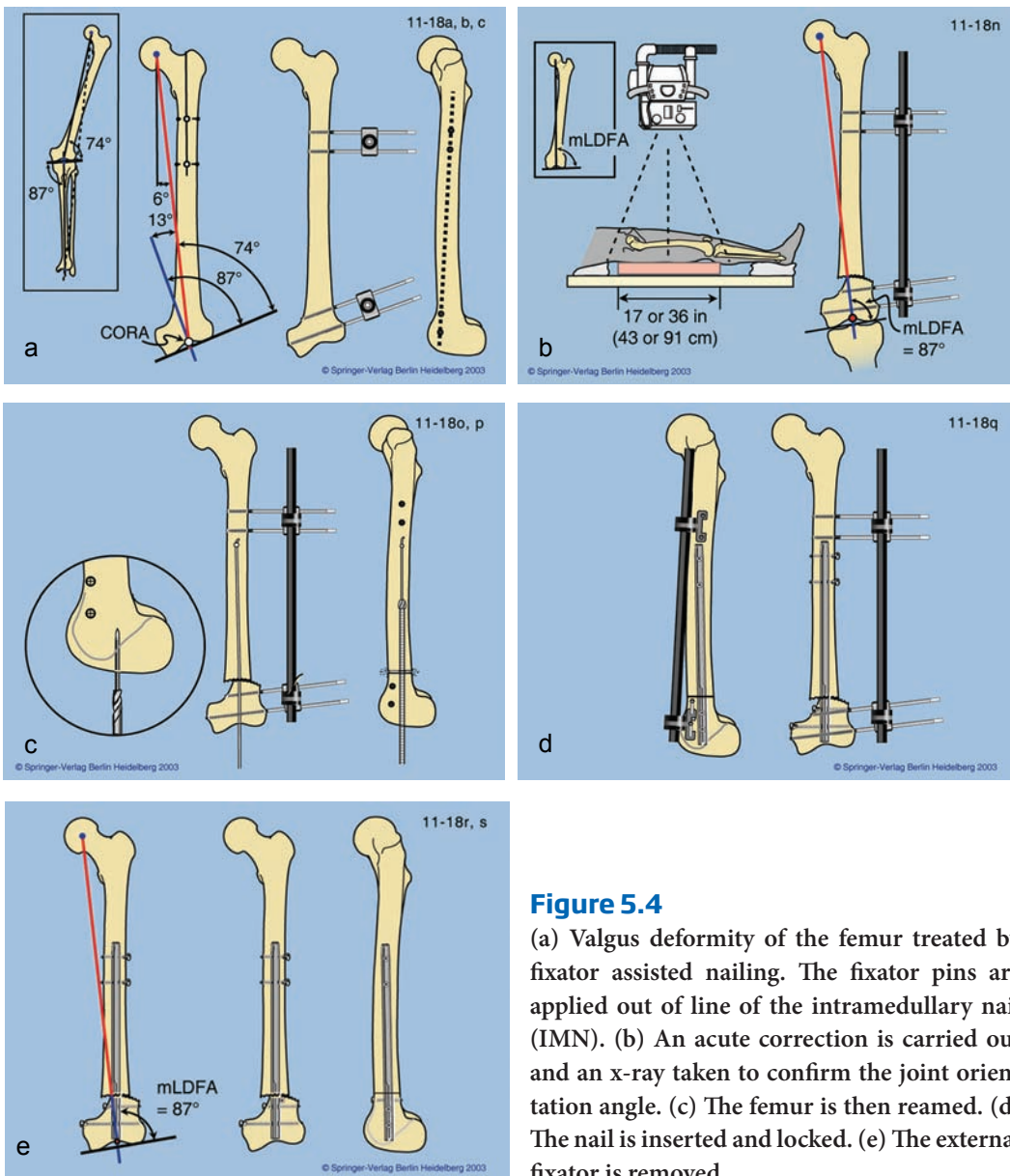
(a) Lengthening over a nail (LON). The nail is inserted and locked proximally. The external fixator is applied with its pins posterior to the nail. (b) After the completion of lengthening the nail is locked distally and the external fixator removed.

the rod at the end of distraction. We succeeded in doing this in a few cases until we encountered a deep infection in one case. The excellent success with LON and one case of intramedullary infection with nailing at the end of distraction stopped us from pursuing this strategy. Perseverance by one of my former clinical fellows, Dr. Robert Rozbruch perfected this technique which is now called “lengthening and then nailing” LATN.<sup>32</sup> LATN is a good method in the tibia and offers the advantage of allowing gradual deformity correction of the upper tibia, prior to nailing. The proximal pins are placed out of the medullary canal and the distal pins, distal to the tip of the nail. LON and LATN were *byproducts* of the lengthy consolidation time in adults by the Ilizarov method and the availability of locking nails. More recently the same concept has been applied using locking plates.<sup>33</sup> Lengthening over plates (LOPs), has been made possible by the introduction of locking plates. The original failures of the Wagner method were due to the use of non-locking plates and failure of bone formation.<sup>34</sup> The locking plate is inserted and locked only at one end. The external fixator is applied avoiding the region of the plate. After distraction the plate is locked and the fixator removed. This allows early removal of the external fixator after first locking the free end of the plate. LOP like LON is a *byproduct* of lengthy consolidation time by the Ilizarov method and the advent of locking plate technology. LOP is a reinvention of the Wagner technique with Ilizarov biology and better plate technology.

##### 5. Fixator assisted nailing (FAN) and fixator assisted plating (FAP) for deformity correction

The Ilizarov method for gradual deformity correction has the advantage of being minimally invasive and very accurate due to its adjustability. Similarly, acute correction with external fixation can also be adjusted in the operating room and check x-rays taken to confirm that the desired alignment has been achieved.<sup>35–39</sup> Both these methods improve

on the accuracy of deformity correction with internal fixation since the latter is not adjustable. Following the successful use of LON, in 1992, I applied external fixator pins out of the path of an intramedullary nail and then performed an osteotomy with acute deformity correction. After adjusting the alignment using the external fixator, I nailed the femur with a locking nail. Fixator assisted nailing (FAN) has the adjustability advantages of external fixation combined with the convenience of internal fixation. By using intramedullary nails it also offers the minimally invasive advantage of external fixation. The external fixator is removed after the nail is locked (Fig. 5.4a–e). FAN was a *byproduct*



**Figure 5.4**

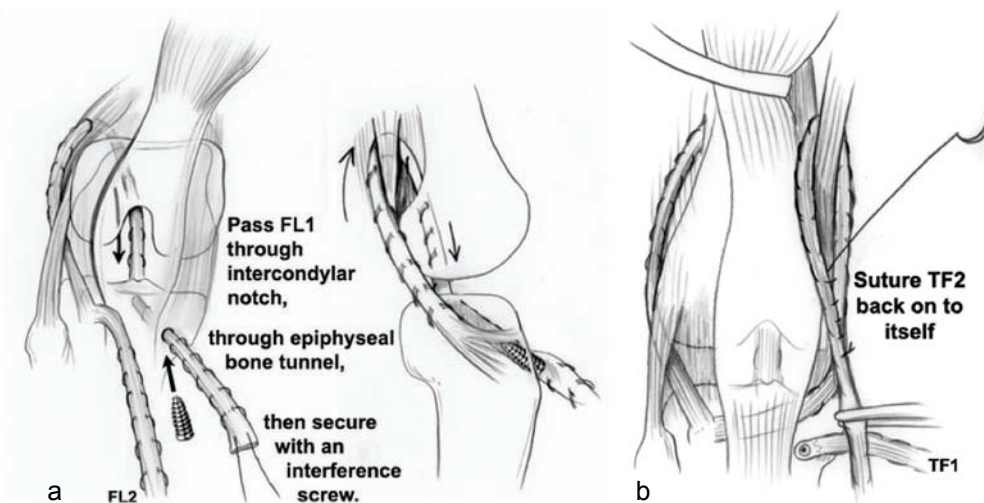
(a) Valgus deformity of the femur treated by fixator assisted nailing. The fixator pins are applied out of line of the intramedullary nail (IMN). (b) An acute correction is carried out and an x-ray taken to confirm the joint orientation angle. (c) The femur is then reamed. (d) The nail is inserted and locked. (e) The external fixator is removed.



of accurate deformity correction with external fixation with a desire to eliminate the external fixator after surgery. More recently fixator assisted plating (FAP) was introduced using the same concepts but applying a percutaneous plate instead of a nail.<sup>40-42</sup>

## 6. New reconstructive procedures for the joints of children with congenital deficiencies

*Superknee (Fig. 5.5a,b)*: Prior to the introduction of the Ilizarov method only the mildest CFD, FH, and tibial hemimelia (TH) cases were considered for leg length equalization surgery. The vast majority were treated by amputation or rotationplasty, and prosthetic fitting. Prior to 1980s lengthening for these conditions was worse than no treatment. The complication rates were high with little gain in length achieved and permanent damage to the hip, knee, and ankle common. Even with Ilizarov's method of spanning the joints the outcome of these joints was not good. In 1994, while trying to reconstruct the knee joint and patella of a CFD patient that had dislocated during lengthening, I came across an article by Lankenskiold et al. on congenital dislocation of the patella.<sup>43</sup> I combined this method with a technique I learned from Grammont to move the patellar tendon in immature children. Since the iliotibial band was the major dislocating force, instead of resecting it I harvested it and used the MacIntosh procedure (I had learned from its author Dr. David Macintosh, my former professor) to create an extra and intra-articular anterior cruciate ligament (ACL). Since the dislocation was a posterolateral rotatory dislocation, I sought to prevent this movement of

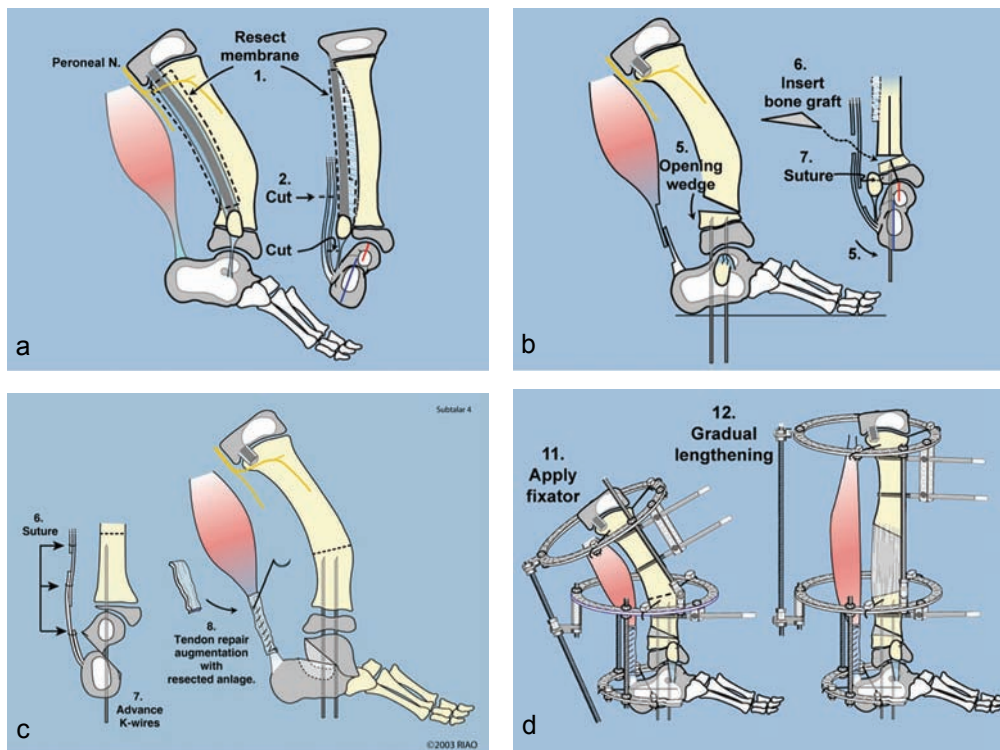


**Figure 5.5**

(a) Superknee procedure: the fascia lata (FL) is harvested and then split into two parts (FL1 & 2). The posterior part (FL1) is passed under the lateral collateral ligament, over the top and then through the proximal tibial epiphysis to be fixed with a screw (Macintosh). (b) The anterior limb of the fascia lata (TF2) is routed under the patellar tendon, through a medical retinacular tunnel and around the adductor magnus tendon. It is sutured to itself and acts as an extra-articular PCL (reverse Macintosh).

the tibia. Since I had harvested the entire ITB and only needed half for the Macintosh, I used the other half as an extra-articular band to prevent external rotation. I ran it under the patellar tendon and around to the side of the femur. I currently loop it around the adductor magnus tendon and suture it to itself. I named this medial extra-articular ligament repair the reverse Macintosh (in honor of my former professor) or extra-articular posterior cruciate ligament (PCL). This combination of procedures is named the “superknee” procedure. It can be performed before lengthening to stabilize a cruciate deficiency knee or after lengthening if a complication occurs. It allows us to salvage previously unsalvageable, unstable congenitally subluxed, or dislocated knees and patellae.

*Superankle (Fig. 5.6a-d):* FH, presented with the problem of fixed equino-valgus of the foot and ankle. Although, the new lengthening techniques excelled at gaining length, persistent or recurrent foot deformity and recurrent valgus deformity at the knee,

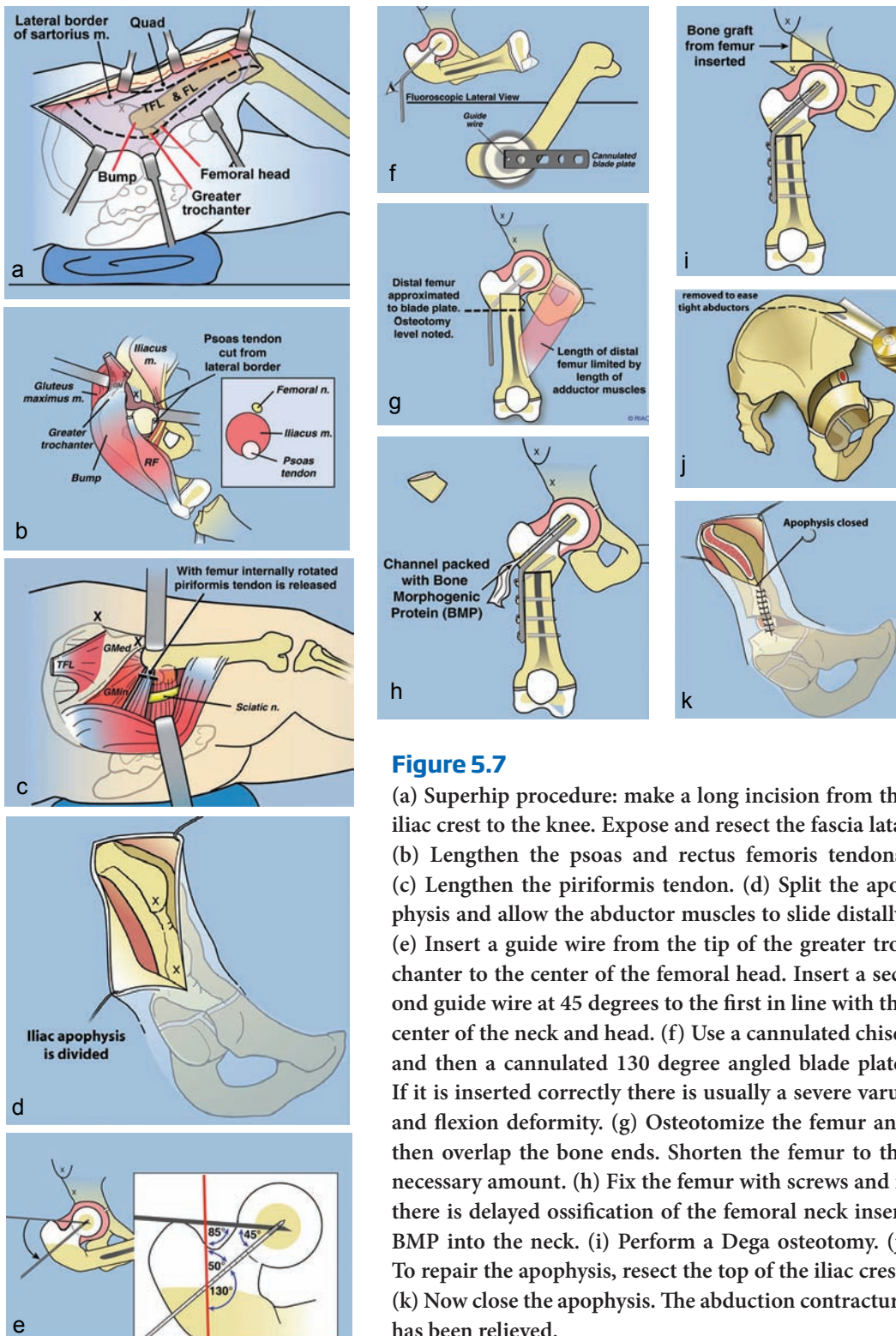


**Figure 5.6**

(a) Superankle procedure for fibular hemimelia: resect the fibular anlage. (b) Lengthen the Achilles and peroneal tendons and if there is malorientation of the ankle joint, perform a supramalleolar opening wedge osteotomy and insert a bone graft and k-wire fixation. (c) If the deformity is predominantly a malunited subtalar coalition, perform a subtalar osteotomy and fix with k-wires. In some cases we perform both supramalleolar and subtalar osteotomies. (d) Apply an external fixator to gradually lengthen and correct the diaphyseal deformity.

remained unsolved problems despite attempts to solve this problem were performed by many surgeons. The problem again was due to the lack of understanding of the pathoanatomy. The equino-valgus foot deformity was being treated the way club foot deformity was treated, using circumferential surgical release. This approach failed for FH. The reason it failed was that the problem is not contracture of the muscles. The problem is malorientation and dysplasia of the ankle joint and malunion of subtalar coalition. This pathoanatomic problem went unrecognized because the ankle joint is invisible radiographically since it is not ossified and the subtalar coalition is also frequently invisible until a much later age. I was initially treating these by either distraction or surgical release of the ankle joint. I noticed the malorientation when I opened the ankle joint to release it. This led to the “superankle” procedure which involves an extra-articular soft tissue release of the ankle joint combined with a supramalleolar varus-extension osteotomy and/or a subtalar coalition osteotomy to slide the calcaneus distal and medial. By reorienting the ankle and/or subtalar joints which were deformed the foot became plantigrade acutely. The deformity did not recur as it had happened with all the other methods of treatment. Once again the problem was solved as a *byproduct* of failed lengthening surgery. Since the foot could now be acutely corrected even in the most dysplastic and deficient feet, lengthening for FH could now be accomplished successfully without recurrent foot deformity. As such, the results of treatment were so good that it is hard to justify amputation which previously was the mainstay of treatment.

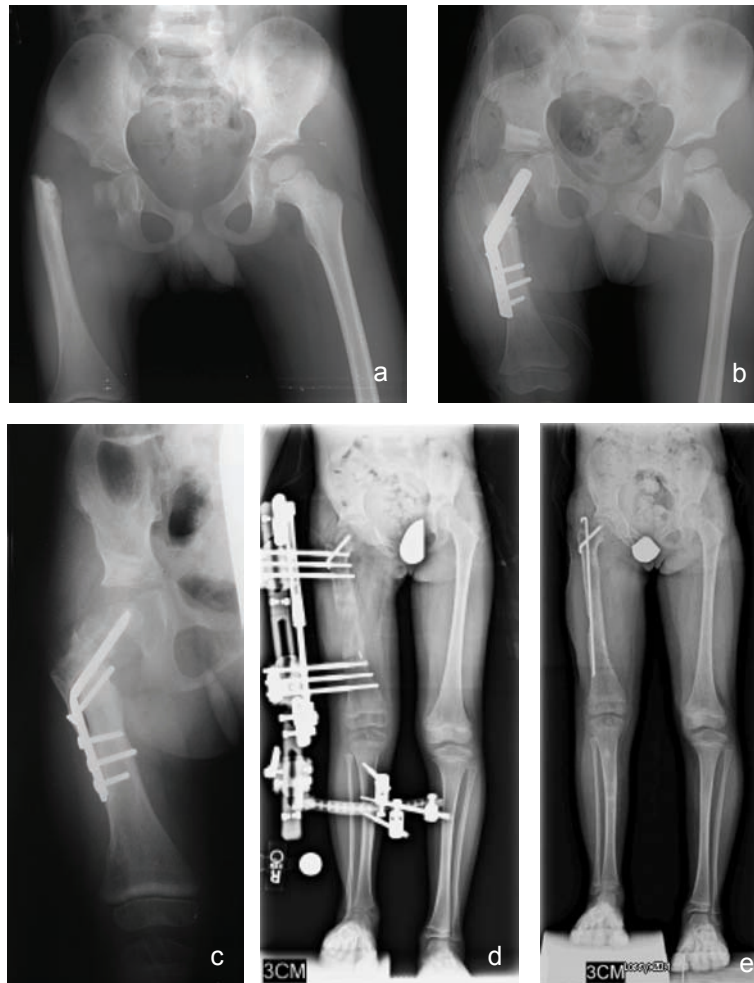
*Superhip 1 (Figs. 5.7a–k, 5.8a–c):* At the hip, only ossified proximal femoral neck cases were lengthenable. The cases with delayed ossification had over 90 degrees of complex angular deformity. Attempts to correct these deformities were met with complete recurrence of the angulation. As a *byproduct* of seeing more and more of these cases, the pathoanatomy of these CFD cases was unraveled. First, no one had ever seen such a volume of such rare cases. Second, successes and failures of treatment were carefully scrutinized and learned. The natural history study by Sanpera and Sparks<sup>44</sup> led to creation of the Paley classification of CFD in 1996. The “eureka” moment, however came as I pondered why the coxa vara always recurred. Looking beyond the bony deformity, I suddenly realized that there was a fixed abduction contracture. Releasing the abduction contracture allowed full correction of the deformity for the first time. At first I did this distally by elevating the abductors with the quadriceps off of the greater trochanter (GT) and then resuturing the conjoint tendon to the GT in its new location. This however led to permanent weakness of the hip abductor muscles. The problem was solved by allowing the muscle body to slide distally off the ilium with the apophysis and shortening of the iliac bone. By understanding the pathoanatomy the complex three-dimensional CFD deformity was unraveled and a new operation to repair this deformity called the “superhip” was born in 1997. With the superhip procedure we can now acutely reconstruct the upper femoral deformity of CFD irrespective of the angle of deformation (deformities of greater than 90 degrees of varus and flexion are common). Recognizing that there was usually a cartilaginous femoral neck present



**Figure 5.7**

(a) Superhip procedure: make a long incision from the iliac crest to the knee. Expose and resect the fascia lata. (b) Lengthen the psoas and rectus femoris tendons. (c) Lengthen the piriformis tendon. (d) Split the apophysis and allow the abductor muscles to slide distally. (e) Insert a guide wire from the tip of the greater trochanter to the center of the femoral head. Insert a second guide wire at 45 degrees to the first in line with the center of the neck and head. (f) Use a cannulated chisel and then a cannulated 130 degree angled blade plate. If it is inserted correctly there is usually a severe varus and flexion deformity. (g) Osteotomize the femur and then overlap the bone ends. Shorten the femur to the necessary amount. (h) Fix the femur with screws and if there is delayed ossification of the femoral neck insert BMP into the neck. (i) Perform a Dega osteotomy. (j) To repair the apophysis, resect the top of the iliac crest. (k) Now close the apophysis. The abduction contracture has been relieved.





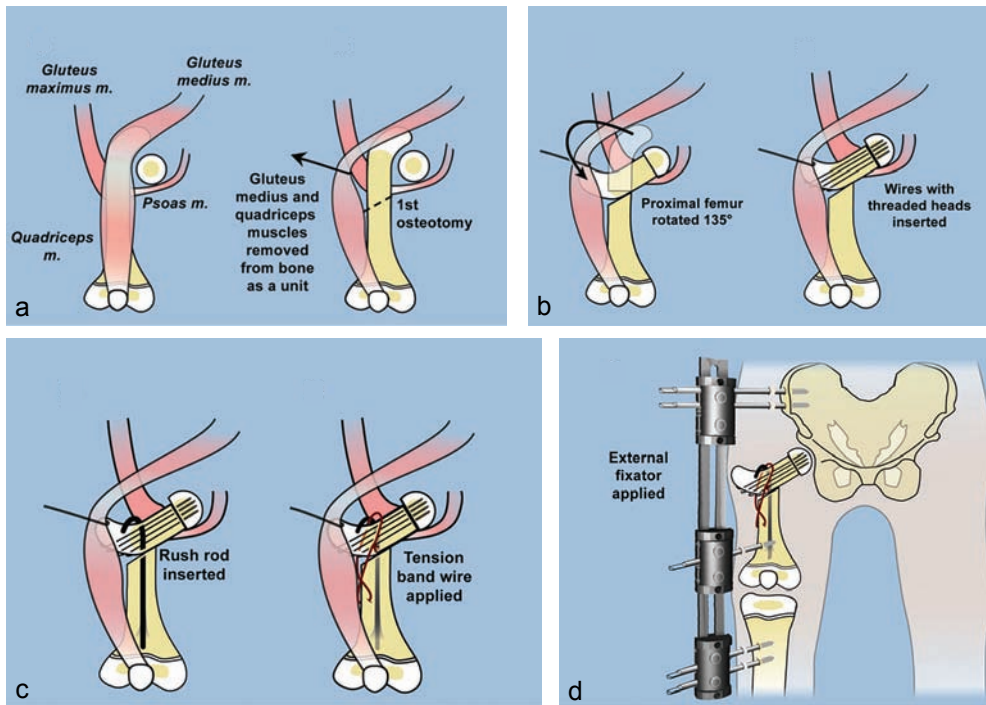
**Figure 5.8**

(a) Congenital femoral deficiency, Paley type 1b. Note the lack of neck ossification. (b) Superhip procedure performed at age 2. BMP inserted into the neck. (c) Ossification occurs in the superior neck where the BMP was administered. (d) 8 cm lengthening of the femur 1 year later. (e) After consolidation. The bone was rodded to prevent fracture.

(which can now be confirmed by MRI) allowed us to apply this correction method to more children at ages as young as 2 years old. Despite the excellent correction and fixation achieved delayed ossification persisted and led to recurrence of deformity until I recognized that unossified cartilage could be ossified by the insertion of bone morphogenetic protein (BMP). The superhip 1 procedure for treatment of CFD Paley type 1b cases is a *byproduct* of failed lengthening surgery for CFD by the Ilizarov method.

*Superhip 2 and 3 (Fig. 5.9 a-d) and rotationplasty (Fig. 5.10a-c):* Unfortunately CFD Paley types 2 and 3 were not treatable by the superhip procedure. In 2001, I developed

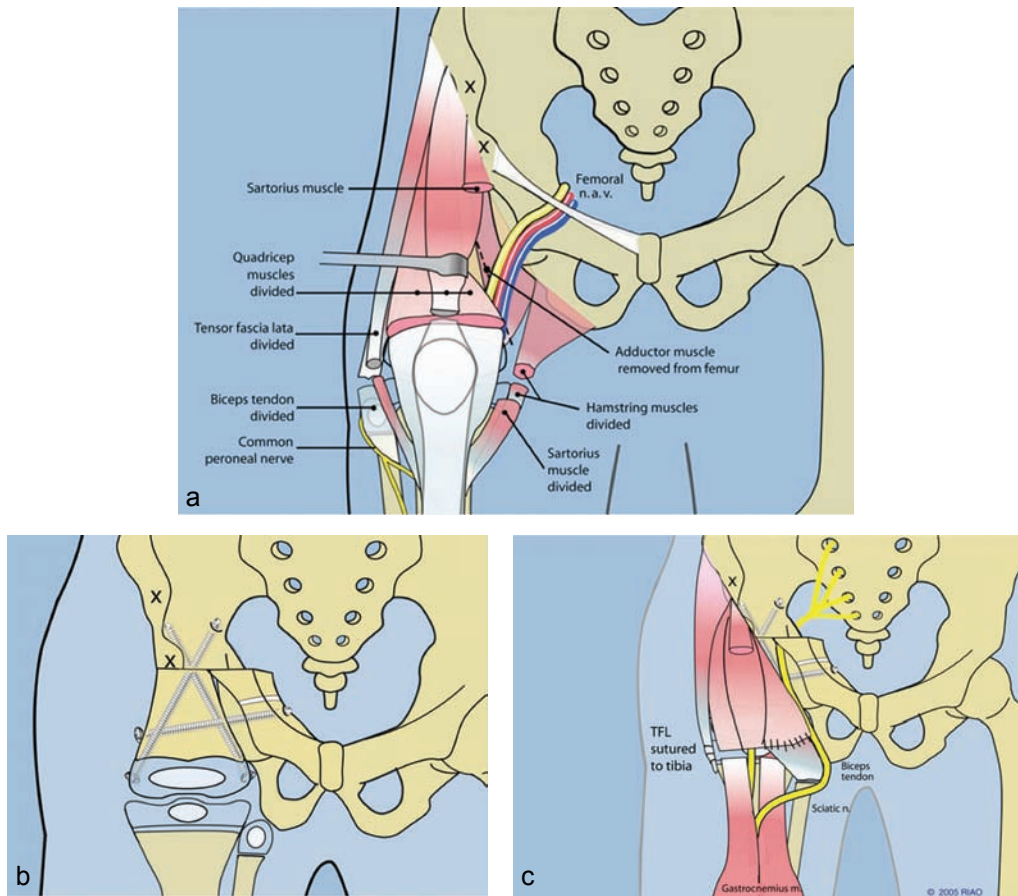




**Figure 5.9**

(a) Superhip2 procedure: the upper femur is moved on a vascular pedicle. (b) The proximal fragment is rotated 135 degrees to be able to act as the femoral neck. It is fixed to the femoral head with threaded K-wires. (c) The neck is fixed in place with a Rush rod and tension band wire. (d) The construct is neutralized using a spanning external fixator from the pelvis to the femur to the tibia.

a new procedure to address the Paley type 2 cases that had a femoral head and GT but no femoral neck. This was named the Superhip 2 procedure. This procedure creates a femoral neck from the upper end of the femur and joins it to the femoral head that is present in the acetabulum. With the advent of the superhip 1 & 2 procedures lengthening was now a possibility for virtually all Paley type 1 and 2 cases. The limiting factor was now the more difficult CFD Paley type 2 and 3. In 2013, the superhip 3 was created to address these cases. In this procedure a new acetabulum using the triradiate cartilage as the roof combined with an interposition and trochanteric arthroplasty have successfully been done to create a hip joint. It is too early to know the results of the Superhip 3 procedure. The most reliable solution for CFD Paley type 3 remains rotationplasty. The need to improve this procedure was also a *byproduct* of failed limb lengthening for CFD Paley type 3. The classic Van Nes rotationplasty was modified for CFD by Gillespie and Krajchich from Toronto.<sup>45,46</sup> Their technique involved fusion of the knee and leaving the hip to float free. As a consequence a severe Trendelenberg and recurrent derotation were frequent complications. Brown, in 1996<sup>47</sup> modified rotationplasty to use a tumor-like racquet incision and fuse the femoral remnant to the pelvis converting the knee into

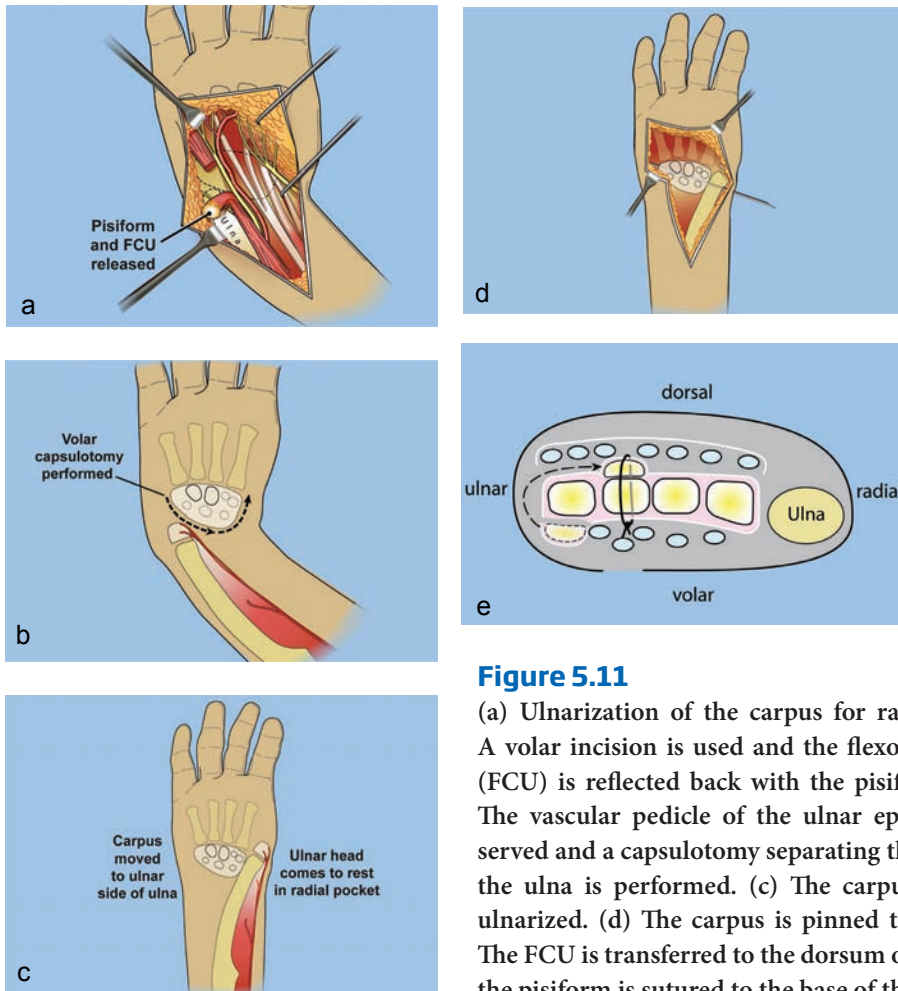


**Figure 5.10**

(a) Paley modification of Brown rotationplasty. Through a racquet incision all of the thigh muscles are detached from their insertions distally. The femoral artery and vein are dissected free of the surrounding structures. (b) The femur is rotated 180 degrees and fixed to a Chiari osteotomy with screws. (c) All of the muscles are reattached in the rotated position to operate the knee as a hip joint.

a hip, and the ankle into a knee. Paley modified the Brown rotationplasty to include a Chiari osteotomy and more distal transfer of the muscle insertions (Fig. 5.10a–c). Most recently I connected the femoral remnant to the femoral head when it was present. Both the Brown and Paley modifications of the rotationplasty preserved the knee joint and converted its function to a hip. Derotation does not occur with the Brown or Paley modifications but is a known complication of the Gillespie and Krajchich type.<sup>45,46</sup>

*Ulnarization* (Fig. 5.11a–e): Treatment of upper extremity deficiencies was similarly impacted. For radial club hand deformity recurrent deformity and growth arrest of the distal ulna were common complications<sup>48</sup> the usual centralization and even of radialization procedures done from a dorsal approach. Distraction methods seemed to be the

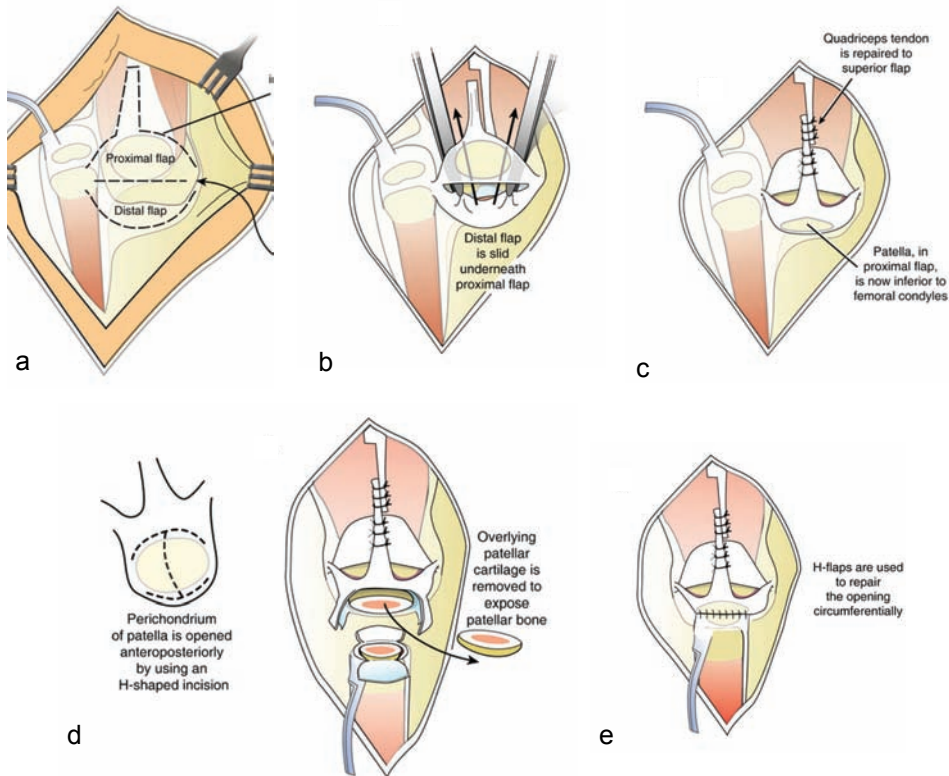


**Figure 5.11**

(a) Ulnarization of the carpus for radial clubhand. A volar incision is used and the flexor carpi ulnaris (FCU) is reflected back with the pisiform bone. (b) The vascular pedicle of the ulnar epiphysis is preserved and a capsulotomy separating the carpus from the ulna is performed. (c) The carpus can now be ulnarized. (d) The carpus is pinned to the ulna. (e) The FCU is transferred to the dorsum of the wrist and the pisiform is sutured to the base of the metacarpal.

solution but turned out to be disappointing since they did not change the recurrence rate.<sup>49</sup> Once again experience with these failed procedures including distraction lead to the development of a new operation through a volar approach. I developed ulnarization in 1999. Using the flexor carpi ulnaris as a tendon transfer instead of the traditional flexor carpi radialis, combined with transfer of the carpus to the ulnar side of the ulna (hence the name 'ulnarization'), lead to a zero recurrence rate and a much stronger dorsiflexion. The volar approach also allowed us to identify the vascular pedicle to the distal ulna and its physis. Therefore, there were no growth arrests. Stabilization of the wrist facilitated lengthening of the forearm for radial clubhand. Ulnarization was a *byproduct* of failed correction of radial clubhand by distraction and by radialization.

*Weber patellar arthroplasty* (Fig. 5.12a-e): TH treatment had resisted all attempts at joint reconstruction by the Brown,<sup>50</sup> and even by the modified pre-distraction Brown procedures. Weber recognized that several of these patients had a patella present and that the patella could be used to substitute the tibial plateau. He developed a vascular



**Figure 5.12**

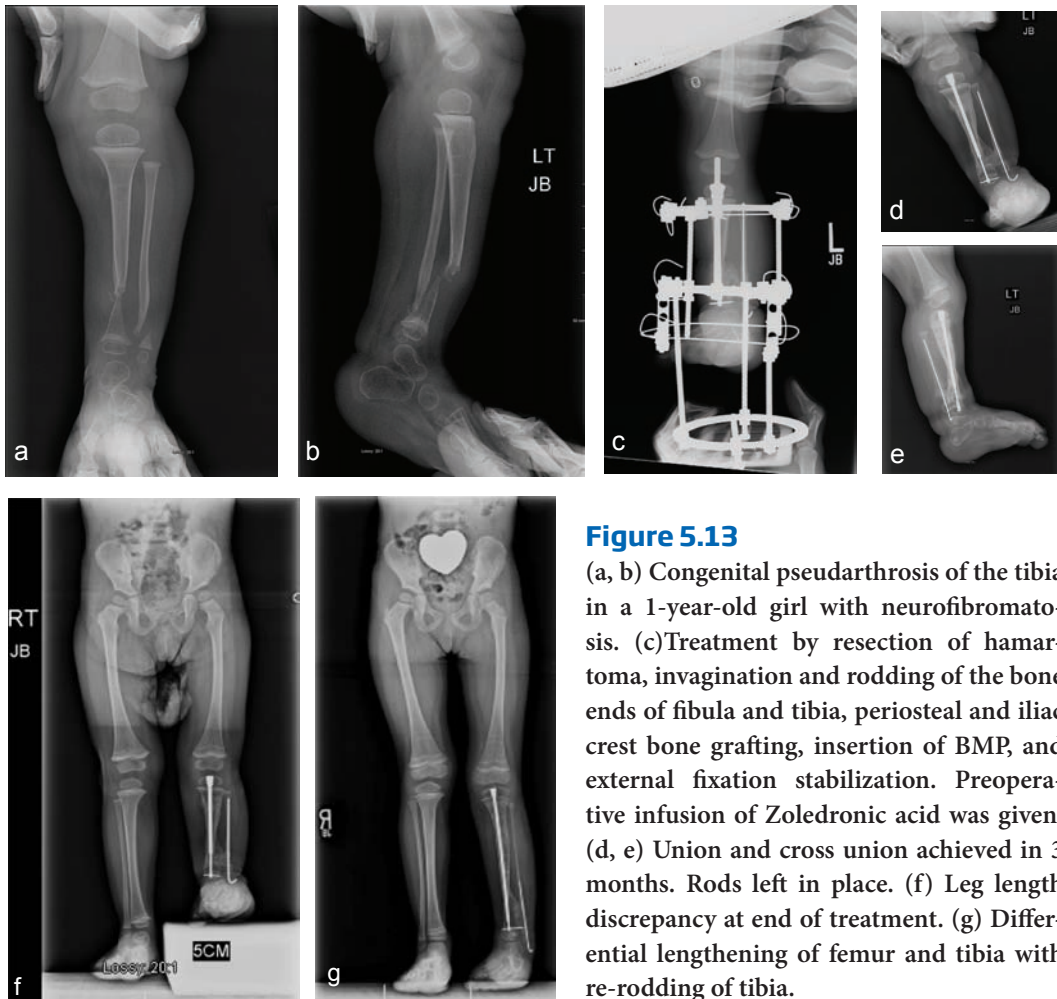
(a) Weber patellar arthroplasty: proximal and distal “visor” flaps are dissected mobilizing the patella on the proximal flap. (b) The flaps are moved up and down, so that the patella rests distal to the end of the femur to act as a tibial plateau. (c) The flaps are repaired to each other. (d) Peri-chondrial flaps are created and the ends of the epiphysis of the fibula and the patella are connected together (e).

pedicle method which I refer to as the Weber patellar arthroplasty.<sup>51</sup> This has made stabilization of the knee possible with remodeling to a normal looking tibial plateau and active knee motion. When a patella is not possible other reconstructive methods creating an ACL-like ligament are used to prevent the subluxation of the centralized fibula, which was very common with the Brown. These methods were *byproducts* of failed distraction treatment of TH.

## 7. New reconstructive procedure for congenital pseudarthrosis of the tibia (CPT)

CPT was previously an unsolved problem. Failure to obtain union or recurrent fracture was the norm and not the exception. While the Ilizarov method was used for many years to treat CPT it was found to be successful to obtain union but not to maintain union.<sup>52</sup> While union rate was high, refracture rate after the Ilizarov was also high. Combining intramedullary fixation with the Ilizarov method reduced but did not eliminate failures and refractures.<sup>53,54</sup> Recognizing this as a periosteal disease





**Figure 5.13**

(a, b) Congenital pseudarthrosis of the tibia in a 1-year-old girl with neurofibromatosis. (c) Treatment by resection of hamartoma, invagination and rodding of the bone ends of fibula and tibia, periosteal and iliac crest bone grafting, insertion of BMP, and external fixation stabilization. Preoperative infusion of Zoledronic acid was given. (d, e) Union and cross union achieved in 3 months. Rods left in place. (f) Leg length discrepancy at end of treatment. (g) Differential lengthening of femur and tibia with re-rodding of tibia.

and using periosteal grafting reduced but did not eliminate refractures.<sup>54,55</sup> The finding that there were too many osteoclasts and treatment with bisphosphonates was a big step forward.<sup>56</sup> Identifying that the BMP production was low and using BMP also helped bone healing<sup>56</sup> Probably the most important factor to prevent recurrence turned out to be creation of a cross union between the tibia and the fibula<sup>57</sup> (Fig. 5.13a–g). Combining these factors has produced a union rate of 100% and a refracture rate of zero. Early treatment which was previously fraught with higher refracture rates was now practical. This also meant that with early treatment secondary leg length discrepancy and ankle and foot deformities were less likely to develop. The end result now can be a completely normal leg and foot. This new method for CPT is a *byproduct* of the high refracture rate after Ilizarov treatment.

## 8. Distraction treatment of joints: e.g., Perthes (Fig. 5.14a–c)

Distraction application to joints according to Ilizarov as well as others like Volkov et al. and Oganessian et al.<sup>58,59</sup> lead early investigators like Aledgheri et al and

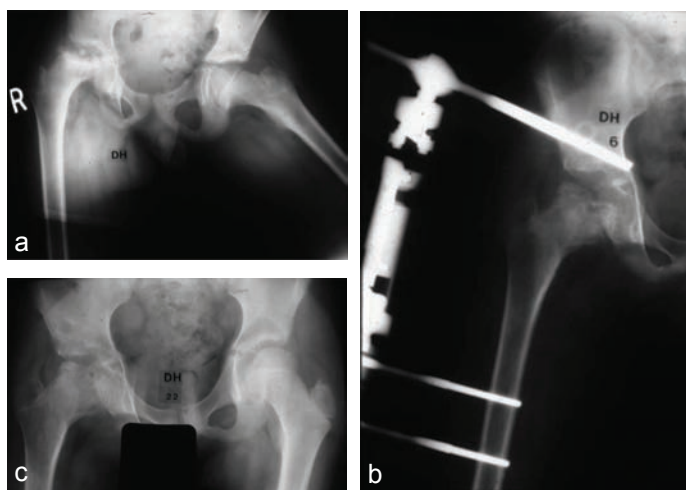


Debatiani et al.<sup>60,61</sup> to apply monolateral devices to distract the hip, knee, ankle, and elbow (arthrodiastasis). Articulated distraction of joints was used to treat joint contracture, joint stiffness, and joint subluxation. I applied joint distraction to treat an 11-year-old boy with severe extrusion, contracture, and stiffness from Perthes in 1989. The result was dramatic. It sped up the reossification of the femoral head, reduced the subluxation, improved the range of motion, and made the femoral head more spherical. Distraction for Perthes has now been corroborated as an effective treatment by surgeons from several different countries.<sup>18,62</sup> Distraction for Perthes is a *byproduct* of the Ilizarov articulated distraction of joints.

## New product advances

### 1. Modularity of monolateral external fixators (Fig. 5.15)

Twenty-five years ago only the Ilizarov circular external fixator offered modularity to address problems of lengthening, angular correction, articulated joint distraction, bone transport, joint fusion, fracture treatment, etc. It could be modified to correct angular deformity with hinges, rotational deformity with rotation constructs, translation deformity with translation constructs, etc. The Ilizarov device could articulate across joints for protection of a joint during lengthening or for correction of joint contractures. The Ilizarov device used only wires. In contrast, monolateral external fixators such as the Orthofix device, had very limited ability to correct deformities and could not articulate across joints. These devices only used threaded half pins for fixation. The monolateral devices had limited modularity. Since then the circular external



**Figure 5.14**

(a) An 11-year-old boy with Perthes disease with significant extrusion and collapse and adduction contracture. (b) Distraction treatment of hip with articulated external fixator. Reduction of the extrusion. (c) Radiograph after 2 years.



**Figure 5.15**

Monolateral external fixator with hinges at the hip and knee for stabilization of joints while permitting flexion and extension movement (Modular Rail System, Smith and Nephew Orthopedics, Memphis, TN, USA).

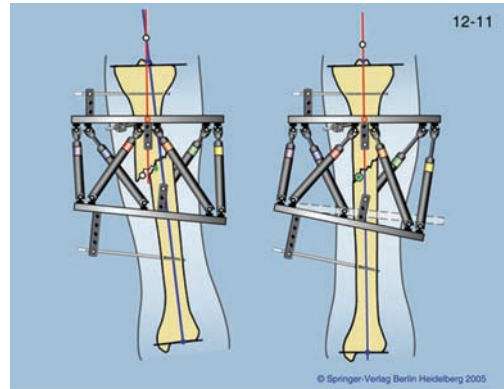
fixators have adapted to use half pins and the monolateral ones added arches to use wires. The monolateral devices now have hinges to articulate across joints and deformities. Some monolateral devices can correct angular, rotation, and translation deformities. The two devices now connect with each other. This modularity has made both circular and monolateral devices much more user friendly and has extended the indications of each.

## 2. Computer dependent external fixation (Fig. 5.16)

In 1994, Charles and Harold Taylor presented their new concept of computer-dependent external fixation. This six-axis correction device allowed changes to be made on the computer screen instead of on the external fixator. This was a huge advance in the circular external fixator technology. Other inventors such as Claus Seide also developed a similar device independently.<sup>63</sup> These devices such as the Taylor Spatial Frame or the Hexapod can correct angulation, rotation, translation, and length deformities simultaneously. On the basis of the success of these devices, newer six-axis correction devices are being developed and the next few years will see a wider variety of what are now termed computer-dependent external fixation devices.

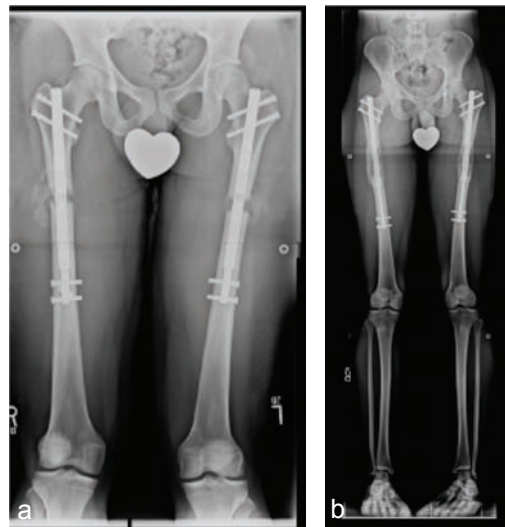
## 3. Implantable limb lengthening (Fig. 5.17 a,b)

While it is commonly recognized that the Soviet Union produced the greatest limb lengthening contributions through the innovations of Ilizarov, few realize that implantable limb lengthening also takes its origin in the Soviet Union. Alexander Bliskunov from Simferopol, Ukraine first published his method in 1983. This was before most of the world had heard of Ilizarov. Bliskunov



**Figure 5.16**

Six-axis deformity correction device with computer-dependent external fixator (Taylor Spatial Frame, Smith and Nephew Orthopedics, Memphis, TN, USA).



**Figure 5.17**

(a) Implantable lengthening nail used for bilateral femoral lengthening for stature (Precice, Ellipse Technologies, Irvine, CA, USA). (b) After 6.5 cm of bilateral femoral lengthening with nails.

developed a telescopic lengthening nail that used a crank shaft connected to the pelvis to drive his mechanism and lengthen the femur.<sup>64</sup> His technology was not available outside of the Soviet Union. It is not surprising that others soon developed other mechanisms to drive telescopic lengthening nails. Baumgart et al. from Germany developed a motorized nail in 1991.<sup>64,66</sup> Guichet et al. from France,<sup>67,68</sup> developed a telescopic nail in 1994 using a ratchet mechanism which rotated the two segments of the nail through the callus of the bone. Cole used this concept to develop a double clutch mechanism to lengthen the ISKD (Intramedullary Skeletal Kinetic Distractor) device marketed by Orthofix.<sup>69,70</sup> This was the first FDA-approved device in 2001. Soubieran developed the Phenix nail which was acquired by Smith and Nephew and awaits FDA approval and release. Ellipse developed the Precice nail with Stuart Green. It is the second FDA-approved implantable lengthening nail and has been in clinical use since 2011. The same company developed the Precice 2 with Dror Paley and released this nail in Nov. 2013. In the near future we expect to see bone transport nails, gradual deformity correction plates, and lengthening plates. The future of non-invasively adjustable implantable devices is the most exciting and promising technologic advance in limb lengthening in the past 25 years.

#### 4. Pharmacologic and biologic advances

As the mechanism of bone formation with limb lengthening has become better understood, the specific pathways for bone and soft tissue regeneration and how they can be modulated has lead to advances in pharmacology and biologic agents.<sup>71-73</sup> The use of bisphosphonate drugs to delay resorption and allow unimpeded bone formation has been useful in treating delayed regenerate bone formation.<sup>74</sup> The use of bone morphogenetic protein to speed regenerate bone formation has also been demonstrated. The role of new therapeutics with concentrated bone marrow stem cells, frozen embryonic stem cells, etc., are still under investigation.<sup>75-81</sup>

### ► SUMMARY

While the history of limb lengthening goes back more than one century, its biggest advances have all occurred in the past 25 years. Its foundations were set by the pioneering, landmark original work, and ideas of Gavril Abramovich Ilizarov. Ilizarov's original ideas have been corroborated and reproduced by surgeons all over the globe. Ilizarov deserves the credit for bringing science to this field. The past 25 years are also bountiful in new ideas, new devices, and new therapeutics. Distraction histogenesis is still a young field of study. There is still a lot of room for innovation and advances. While the first 100 years was the story of external fixation and distraction osteogenesis, the next 100 years will be the story of implantable distraction devices, biofeedback controls for internal and external fixation, and the modulation of molecular biology, and regenerative biology to orthopedics. Many of the genetic conditions currently being treated will have medical instead of surgical solutions and new applications of distraction biology will be found.



### Key Learning Points

- ❖ Limb lengthening has evolved from traction bed mounted devices to portable external fixation to implantable limb lengthening.
- ❖ Distraction osteogenesis is best achieved by control of rate and rhythm of distraction of a low energy osteotomy without initial diastasis with preservation of the periosteal and endosteal elements of the bone.
- ❖ During the last 25 years the methods of Ilizarov have been reproduced. While overcoming the obstacles of bone and soft tissue regeneration, new obstacles such as joint reconstruction of congenital deficiencies required developing a wide variety of new operations that previously were not considered. These new operations are called *byproducts* of the Ilizarov method.
- ❖ External fixation while a means to an end is not well liked by surgeons and patients alike. Efforts to shorten the external fixation treatment time lead to the development of LON, LOP, FAN, and FAP.
- ❖ Parallel efforts to eliminate the need for external fixation lead others to develop fully implantable lengthening devices. We are now in the era of implantable lengthening nails and await new implantable solutions for bone transport, deformity correction, etc.
- ❖ The future of this young field will include dynamic implants and biologic advances in cellular and molecular technology.

## REFERENCES

1. Paley D. Current techniques of limb lengthening, *J Pediatr Orthop* 1988; Jan–Feb 8(1): 73–92.
2. Varghese RA, Dhawale AA, Zavaglia BC, Slobogean BL, Mulpuri K. Citation classics in pediatric orthopaedics. *J Pediatr Orthop* 2013; 33(6): 667–71.
3. Codivilla A. On the means of lengthening, in the lower limbs, the muscles and tissues which are shortened through deformity. *J Bone Joint Surg Am* 1905; 2(2): 353–69.
4. Putti V. The operative lengthening of the femur 1921. *Clin Orthop Relat Res* 1990 Jan; (250): 4–7.
5. Allan FG. Bone lengthening. *J Bone Joint Surg Br* 1948 Aug; 30B(3): 490–505.
6. Allan FG. Leg-lengthening. *Br Med J* 1951 Feb 3; 1(4700): 218–22.
7. Abbott LC. Lengthening of the lower extremities. *Cal West Med* 1932 Jan; 36(1): 6–13.
8. Abbott LC, Saunders JB. The operative lengthening of the tibia and fibula: a preliminary report on the further development of the principles and technic. *Ann Surg* 1939 Dec; 110(6): 961–91.
9. Anderson WV. Leg lengthening. *J Bone Joint Surg Br* 1952; 34: 150.
10. Bost FC, Larsen LJ. Experiences with lengthening of the femur over an intramedullary rod. *J Bone Joint Surg Am* 1956 Jun; 38-A(3): 567–84.

11. Aronson J. Temporal and spatial increases in blood flow during distraction osteogenesis. *Clin Orthop Relat Res* 1994 Apr; (301): 124–31.
12. Aronson J, Harrison B, Boyd CM, Cannon DJ, Lubansky HJ, Stewart C. Mechanical induction of osteogenesis. Preliminary studies. *Ann Clin Lab Sci* 1988 May–Jun; 18(3): 195–203.
13. Aronson J, Harrison BH, Stewart CL, Harp JH Jr. The histology of distraction osteogenesis using different external fixators. *Clin Orthop Relat Res* 1989 Apr; (241): 106–16.
14. Aronson J, Harp JH Jr. Factors influencing the choice of external fixation for distraction osteogenesis. *Instr Course Lect* 1990; 39: 175–83.
15. Kojimoto H, Yasui N, Goto T, Matsuda S, Shimomura Y. Bone lengthening in rabbits by callus distraction. The role of periosteum and endosteum. *J Bone Joint Surg Br* 1988 Aug; 70(4): 543–9.
16. Yasui N, Kojimoto H, Shimizu H, Shimomura Y. The effect of distraction upon bone, muscle, and periosteum. *Orthop Clin North Am* 1991 Oct; 22(4): 563–7.
17. Yasui N, Sato M, Ochi T, Kimura T, Kawahata H, Kitamura Y, Nomura S. Three modes of ossification during distraction osteogenesis in the rat. *J Bone Joint Surg Br* 1997 Sep; 79(5): 824–30.
18. Paley D, Herzenberg JE. *Principles of Deformity Correction*. 1st ed. Berlin: Springer-Verlag. 2002. (Corr. 3rd printing 2005.)
19. Sabharwal S, Paley D, Bhav A, Herzenberg JE. Growth patterns after lengthening of congenitally short lower limbs in young children. *J Pediatr Orthop* 2000; 20: 137–145.
20. Paley D, Bhav A, Herzenberg JE, Bowen JR. Multiplier method for predicting limb-length discrepancy. *J Bone Joint Surg Am* 2000 Oct; 82-A(10): 1432–46.
21. Aguilar JA, Paley D, Paley J, Santpure S, Patel M, Bhav A, Herzenberg JE. Clinical validation of the multiplier method for predicting limb length at maturity, part I. *J Pediatr Orthop* 2005 Mar–Apr; 25(2): 186–91.
22. Aguilar JA, Paley D, Paley J, Santpure S, Patel M, Herzenberg JE, Bhav A. Clinical validation of the multiplier method for predicting limb length discrepancy and outcome of epiphysiodesis, part II. *J Pediatr Orthop* 2005 Mar–Apr; 25(2): 192–6.
23. Paley J, Gelman A, Paley D, Herzenberg JE. The prenatal multiplier method for prediction of limb length discrepancy. *Prenat Diagn* 2005 Jun; 25(6): 435–8.
24. Paley J, Talor J, Levin A, Bhav A, Paley D, Herzenberg JE. The multiplier method for prediction of adult height. *J Pediatr Orthop* 2004 Nov–Dec; 24(6): 732–7.
25. Lamm BM, Paley D, Kurland DB, Matz AL, Herzenberg JE. Multiplier method for predicting adult foot length. *J Pediatr Orthop* 2006 Jul–Aug; 26(4): 444–8.
26. Paley D, Gelman A, Shualy MB, Herzenberg JE. Multiplier method for limb-length prediction in the upper extremity. *J Hand Surg Am* 2008 Mar; 33(3): 385–91. doi: 10.1016/j.jhsa.2007.11.007.
27. Fischgrund J, Paley D, Suter C. Variables affecting time to bone healing during limb lengthening. *Clin Orthop Relat Res* 1994 Apr; (301): 31–7.
28. Wagner H. Operative lengthening of the femur. *Clin Orthop Relat Res* 1978 Oct; (136): 125–42.



29. Wasserstein I. Twenty-five years' experience with lengthening of shortened lower extremities using cylindrical allografts. *Clin Orthop Relat Res* 1990 Jan; (250): 150–3.
30. Paley D, Herzenberg JE, Paremian G, Bhave A. Femoral lengthening over an intramedullary nail. A matched-case comparison with Ilizarov femoral lengthening. *J Bone Joint Surg Am* 1997 Oct; 79(10): 1464–80.
31. Paley D, Herzenberg JE, Maar D, Tetsworth KT. Femoral lengthening by simultaneous external fixation and intramedullary rodding. *J Orthop Trauma* 1993; 7:178.
32. Rozbruch SR, Kleinman D, Fragomen AT, Ilizarov S. Limb lengthening and then insertion of an intramedullary nail: a case-matched comparison. *Clin Orthop Relat Res* 2008 Dec; 466(12): 2923–32. doi: 10.1007/s11999-008-0509-8. Epub 2008 Sep 18.
33. Iobst CA, Dahl MT. Limb lengthening with submuscular plate stabilization: a case series and description of the technique. *J Pediatr Orthop* 2007; Jul–Aug; 27(5): 504–9.
34. Guarniero R, Barros Júnior TE. Femoral lengthening by the Wagner method. *Clin Orthop Relat Res* 1990 Jan; 250: 154–9.
35. Paley D, Herzenberg JE, Bor N. Fixator-assisted nailing of femoral and tibial deformities. *Tech Orthop* 1997; 12: 260–75.
36. Paley D, Herzenberg JE. *Principles of Deformity Correction, Hardware and Osteotomy Considerations Chapter 11*. Springer-Verlag 1st ed. 2002. Corr. 3rd printing 2005.
37. Jasiewicz B, Kacki W, Tesiorowski M, Potaczek T. [Results of femoral lengthening over an intramedullary nail and external fixator]. *Chir Narzadow Ruchu Ortop Pol* 2008 May–Jun; 73(3): 177–83.
38. Kocaoglu M, Eralp L, Bilen FE, Balci HI. Fixator-assisted acute femoral deformity correction and consecutive lengthening over an intramedullary nail. *J Bone Joint Surg Am* 2009 Jan; 91(1): 152–9. doi: 10.2106/JBJS.H.00114.
39. Bilen FE, Kocaoglu M, Eralp L, Balci HI. Fixator-assisted nailing and consecutive lengthening over an intramedullary nail for the correction of tibial deformity. *J Bone Joint Surg Br* 2010 Jan; 92(1): 146–52.
40. El-Rosasy MA, El-Sallakh SA. Distal tibial hypertrophic nonunion with deformity: treatment by fixator-assisted acute deformity correction and LCP fixation. *Strategies Trauma Limb Reconstr* 2013 Apr; 8(1): 31–5. doi: 10.1007/s11751-012-0150-7. Epub 2012 Oct 27.
41. Eidelman M, Keren Y, Norman D. Correction of distal femoral valgus deformities in adolescents and young adults using minimally invasive fixator-assisted locking plating (FALP). *J Pediatr Orthop B*. 2012 Nov; 21(6): 558–62. doi: 10.1097/BPB.0b013e328358f884.
42. Seah KT, Shafi R, Fragomen AT, Rozbruch SR. Distal femoral osteotomy: is internal fixation better than external? *Clin Orthop Relat Res* 2011 Jul; 469(7): 2003–11. doi: 10.1007/s11999-010-1755-0. Epub 2011 Jan 6.
43. Langenskiöld A, Ritsilä V. Congenital dislocation of the patella and its operative treatment. *J Pediatr Orthop* 1992 May–Jun; 12(3): 315–23.
44. Sanpera I Jr, Sparks LT. Proximal femoral focal deficiency: does a radiologic classification exist? *J Pediatr Orthop* 1994 Jan–Feb; 14(1): 34–8.
45. Torode IP, Gillespie R. Rotationplasty of the lower limb for congenital defects of the femur. *J Bone Joint Surg Br*. 1983 Nov; 65(5): 569–73.

46. Krajbich JI. Modified Van Nes rotationplasty in the treatment of malignant neoplasms in the lower extremities of children. *Clin Orthop Relat Res*. 1991 Jan; 262: 74–7.
47. Brown KL. Resection, rotationplasty, and femoropelvic arthrodesis in severe congenital femoral deficiency. A report of the surgical technique and three cases. *J Bone Joint Surg Am* 2001 Jan; 83-A(1): 78–85.
48. Buck-Gramcko D. Radialization as a new treatment for radial club hand. *J Hand Surg Am* 1985 Nov; 10(6 Pt 2): 964–8.
49. Kessler I. Centralisation of the radial club hand by gradual distraction *J Hand Surg Br* 1989 Feb; 14(1): 37–42.
50. Brown FW. Construction of a knee joint in congenital total absence of the tibia. *J Bone Joint Surg Am* 1965; 47: 695–704.
51. Weber M. A new knee arthroplasty versus Brown procedure in congenital total absence of the tibia: a preliminary report. *J Pediatr Orthop B* 2002 Jan; 11(1): 53–9.
52. El-Rosasy MA, Paley D, Herzenberg JE. Congenital pseudarthrosis of the tibia. In: Rozbruch SR, Ilizarov S (eds): *Limb Lengthening and Reconstruction Surgery*. New York: Informa Healthcare, 2007, ch 34, pp 485–94.
53. Grill F, Bollini G, Dungal P, Fixsen J, Hefti F, Ippolito E, Romanus B, Tudisco C, Wientroub S. Treatment approaches for congenital pseudarthrosis of tibia: results of the EPOS multi-center study: European Paediatric Orthopaedic Society (EPOS). *J Pediatr Orthop B*. 2000; 9: 75–89.
54. Thabet AM, Paley D, Kocaoglu M, Eralp L, Herzenberg JE, Ergin ON. Periosteal grafting for congenital pseudarthrosis of the tibia: a preliminary report. *Clin Orthop Relat Res* 2008 Dec; 466(12): 2981–94.
55. Hermanns-Sachweh B, Senderek J, Alfer J, Klosterhalfen B, Büttner R, Füzesi L, Weber M. Vascular changes in the periosteum of congenital pseudarthrosis of the tibia. *Pathol Res Pract* 2005;201: 305–12.
56. Schindeler A, Ramachandran M, Godfrey C, Morse A, McDonald M, Mikulec K, Little DG. Modeling bone morphogenetic protein and bisphosphonate combination therapy in wild-type and Nf1 haploinsufficient mice. *J Orthop Res* 2008; 26: 65–74.
57. Paley D. *Congenital Pseudarthrosis of the Tibia: Combined Pharmacologic and Surgical Treatment Using Biphosphonate Intravenous Infusion and Bone Morphogenic Protein with Periosteal and Cancellous Autogenous Bone Grafting, Tibio-Fibular Cross Union, Intramedullary, Bone Grafting*. Dr Alessandro Zorzi (Ed.), (2012). ISBN: 978-953-51-0324-0, InTech, DOI: 10.5772/31149.
58. Volkov MV, Ogenesian OV. Restoration of function in the knee and elbow with a hinge-distraction apparatus. *J Bone Joint Surg Am* 1975 Jul; 57(5): 591–600.
59. Ogenesian OV, Istomina IS, Kuzmin VI. Treatment of equinovarus deformity in adults with the use of a hinged distraction++ apparatus. *J Bone Joint Surg Am* 1996 Apr; 78(4): 546–56.
60. Aldegheri R, Trivella G, Saleh M. Articulated distraction of the hip: Conservative surgery for arthritis in young patients. *Clin Orthop* 1994; 301: 94–101.
61. De Bastiani G, Aldegheri R, Renzi-Brivio L, Trivella G. Limb lengthening by callus distraction (callotaxis). *J Pediatr Orthop* 1987 Mar–Apr; 7(2): 129–34.

62. Paley D. Treatment of Perthes Disease of the Hip by Joint Distraction (in press).
63. Paley D. History and science behind the six-axis correction external fixation devices in orthopaedic surgery. *Oper Tech Orthop* 2011; 21(2), 125–28.
64. Bliskunov AI, [Lengthening of the femur using implantable appliances]. *Acta Chir Orthop Traumatol Tech* 1984 Dec; 51(6): 454–66.
65. Baumgart R, Betz A, Schweiberer L. [First fully implantable intramedullary system for callus distraction—intramedullary nail with programmable drive for leg lengthening and segment displacement. Principles and initial clinical results]. *Chirurg* 1990 Aug; 61(8): 605–9.
66. Baumgart R, Betz A, Schweiberer L. A fully implantable motorized intramedullary nail for limb lengthening and bone transport. *Clin Orthop Relat Res* 1997 Oct; 343: 135–43.
67. Guichet JM, Grammont PM, Trouilloud P. [A nail for progressive lengthening. An animal experiment with a 2-year follow-up]. *Chirurgie* 1992; 118(6–7): 405–10.
68. Guichet JM, Casar RS, Mechanical characterization of a totally intramedullary gradual elongation nail. *Clin Orthop Relat Res* 1997 Apr; 337: 281–90.
69. Cole JD, Justin D, Kasparis T, DeVlught D, Knobloch C. The intramedullary skeletal kinetic distractor (ISKD): first clinical results of a new intramedullary nail for lengthening of the femur and tibia. *Injury* 2001 Dec; 32 (Suppl 4): SD129–39.
70. Burghardt RD, Herzenberg JE, Specht SC, Paley D. Mechanical failure of the intramedullary skeletal kinetic distractor in limb lengthening. *J Bone Joint Surg Br* 2011 May; 93(5): 639–43.
71. Siddiqui NA, Owen JM. Clinical advances in bone regeneration. *Curr Stem Cell Res Ther* 2013 May; 8(3): 192–200.
72. Haque T, Hamade F, Alam N, Kotsioprifitis M, Lauzier D, St-Arnaud R, Hamdy RC. Characterizing the BMP pathway in a wild type mouse model of distraction osteogenesis. *Bone* 2008 Jun; 42(6): 1144–53.
73. Makhdom AM, Hamdy RC. The role of growth factors on acceleration of bone regeneration during distraction osteogenesis. *Tissue Eng Part B Rev*. 2013 Oct; 19(5): 442–53. doi: 10.1089/ten.TEB.2012.0717. Epub 2013 Jun 15.
74. Kiely P, Ward K, Bellemore C M, Briody J, Cowell CT, Little DG. Bisphosphonate rescue in distraction osteogenesis: a case series. *J Pediatr Orthop* 2007 Jun; 27(4): 467–71.
75. Lesaichot V, Leperlier D, Viateau V, Richarme D, Petite H, Sailhan F. The influence of bone morphogenic protein-2 on the consolidation phase in a distraction osteogenesis model. *Injury* 2011 Dec; 42(12): 1460–6. doi: 10.1016/j.injury.2011.05.039. Epub 2011 Jul 2.
76. Jin L, Li X. Growth differentiation factor 5 regulation in bone regeneration. *Curr Pharm Des* 2013; 19(19): 3364–73.
77. Sato K, Haruyama N, Shimizu Y, Hara J, Kawamura H. Osteogenesis by gradually expanding the interface between bone surface and periosteum enhanced by bone marrow stem cell administration in rabbits. *Oral Surg Oral Med Oral Pathol Oral Radiol Endod* 2010 Jul; 110(1): 32–40. doi: 10.1016/j.tripleo.2009.11.005. Epub 2010 Feb 26.
78. Zhao ZY, Shao L, Zhao HM, Zhong ZH, Liu JY, Hao CG. Osteogenic growth peptide accelerates bone healing during distraction osteogenesis in rabbit tibia. *J Int Med Res* 2011; 39(2): 456–63.

79. Latalski M, Elbatrawy YA, Thabet AM, Gregosiewicz A, Raganowicz T, Fatyga M. Enhancing bone healing during distraction osteogenesis with platelet-rich plasma. *Injury* 2011 Aug; 42(8): 821–4.
80. Ma D, Mao T.[Cell-based approaches to promote bone regeneration in distraction osteogenesis]. *Zhongguo Xiu Fu Chong Jian Wai Ke Za Zhi* 2012 Dec; 26(12): 1512–5.
81. RolimFilho EL, Larrazabal MC, da Costa LF Jr, dos Santos SM, dos Santos RM, Aguiar JL. Effect of autologous stem cells on regenerated bone during distraction osteogenesis by Ilizarov technique in the radius of dogs. Histomorphometric analysis. *Acta Cir Bras* 2013 Aug; 28(8): 574–81.